

**Profile**

Tumour necrosis factor is a cytokine of which 2 forms have been identified with similar biological properties: TNF $\alpha$  or cachectin, which is produced mainly by macrophages, and TNF $\beta$  or lymphotxin, which is produced by lymphocytes. Various recombinant forms of TNF $\alpha$ , both human and mouse, are available: the names sonermin and senternef have been used for such products.

The antitumour effects of tumour necrosis factor *in vitro* and in animals have prompted investigation of recombinant TNF $\alpha$  in the treatment of cancer either alone or with other cytokines such as interleukin-2 or the interferons. Tasonermin is a recombinant TNF $\alpha$  used with melphalan (p.742) for soft tissue sarcomas. It is given by mild hyperthermic isolated limb perfusion at a total dose of 3 mg for an upper limb and 4 mg for a lower limb.

Leakage of tasonermin into the systemic circulation should not exceed 10%, as severe toxicity may occur. Local adverse effects include skin reactions, oedema, and pain; less commonly, vascular thrombosis, onycholysis, or severe tissue damage have occurred. Systemic effects include fever, chills, nausea and vomiting, arrhythmias, hepatotoxicity, and infections. Shock or hypotension, neurological disorders, thrombocytopenia, leucopenia, acute renal failure, and hypersensitivity reactions have all been reported.

## ♦ References.

- van Der Veen AH, *et al.* An overview on the use of TNF- $\alpha$ : our experience with regional administration and developments towards new opportunities for systemic application. *Anticancer Res* 2000; **20**: 3467-74.
- Libutti SK, *et al.* Technique and results of hyperthermic isolated hepatic perfusion with tumor necrosis factor and melphalan for the treatment of unresectable hepatic malignancies. *J Am Coll Surg* 2000; **191**: 519-30.
- Lejeune FJ, *et al.* Limb salvage by neoadjuvant isolated perfusion with TNF $\alpha$  and melphalan for non-resectable soft tissue sarcoma of the extremities. *Eur J Surg Oncol* 2000; **26**: 669-78.
- Eggermont AM, ten Hagen TL. Tumor necrosis factor-based isolated limb perfusion for soft tissue sarcoma and melanoma: ten years of successful antitumor therapy. *Curr Oncol Rep* 2003; **5**: 79-80.
- ten Hagen TL, Eggermont AM. Solid tumor therapy: manipulation of the vasculature with TNF. *Technol Cancer Res Treat* 2003; **2**: 195-203.
- Noorda EM, *et al.* Isolated limb perfusion with tumor necrosis factor- $\alpha$  and melphalan for patients with unresectable soft tissue sarcoma of the extremities. *Cancer* 2003; **98**: 1483-90.
- Corti A. Strategies for improving the anti-neoplastic activity of TNF by tumor targeting. *Methods Mol Med* 2004; **98**: 247-64.

**Units.** The first International Standard for human tumour necrosis factor  $\alpha$ , which contained 40 000 international units/ampoule, was considered unsuitable for the assay of recombinant mouse tumour necrosis factor  $\alpha$ , for human tumour necrosis factor  $\beta$ , or for preparations of tumour necrosis factor  $\alpha$  of modified structure.<sup>1</sup> The second International Standard for human tumour necrosis factor  $\alpha$  has been established as having a potency of 46 500 international units/ampoule.<sup>2</sup>

The first Reference Reagent for tumour necrosis factor  $\beta$  had an assigned potency of 150 000 units/ampoule.<sup>3</sup>

- WHO. WHO expert committee on biological standardization: forty-second report. *WHO Tech Rep Ser* 822 1992. Available at: [http://whqlibdoc.who.int/trs/WHO\\_TRS\\_822.pdf](http://whqlibdoc.who.int/trs/WHO_TRS_822.pdf) (accessed 01/08/08)
- WHO. WHO expert committee on biological standardization: fifty-fourth report. *WHO Tech Rep Ser* 927 2005. Available at: [http://whqlibdoc.who.int/trs/WHO\\_TRS\\_927\\_eng.pdf](http://whqlibdoc.who.int/trs/WHO_TRS_927_eng.pdf) (accessed 01/08/08)
- WHO. WHO expert committee on biological standardization: forty-seventh report. *WHO Tech Rep Ser* 878 1998. Available at: [http://libdoc.who.int/trs/WHO\\_TRS\\_878.pdf](http://libdoc.who.int/trs/WHO_TRS_878.pdf) (accessed 01/08/08)

**Preparations**

**Proprietary Preparations** (details are given in Part 3)

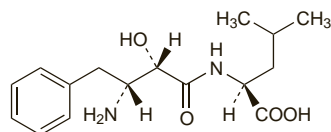
**Belg.:** Beromun†; **Cz.:** Beromun; **Fr.:** Beromun†; **Gr.:** Beromun; **Ital.:** Beromun; **Neth.:** Beromun; **Port.:** Beromun; **Spain:** Beromun; **Swed.:** Beromun.

**Ubenimex (rINN)**

NK-421; NSC-265489; Ubénimex; Ubenimexum. (–)-N-[(2S,3R)-3-Amino-2-hydroxy-4-phenylbutyl]-L-leucine.

УБЕНИМЕКС

$C_{16}H_{24}N_2O_4 = 308.4$ .  
CAS — 58970-76-6.



**Pharmacopoeias.** In *Chin.*

**Profile**

Ubenimex is a peptide derived from *Streptomyces olivoreticuli*. It is reported to have antineoplastic and immunostimulant properties. It has been used in the adjuvant treatment of acute myeloid

leukaemia and is under investigation for the treatment of lung cancer. Adverse effects include gastrointestinal and hepatic function disturbances, skin rashes, headache, and paraesthesias.

## ♦ References.

- Ichinose Y, *et al.* Randomized double-blind placebo-controlled trial of bestatin in patients with resected stage I squamous-cell lung carcinoma. *J Natl Cancer Inst* 2003; **95**: 605-10.

**Preparations**

**Proprietary Preparations** (details are given in Part 3)

**Cz.:** Bestatin†; **Jpn.:** Bestatin.

**Valrubicin (USAN, rINN)**

AD-32; NSC-246131; N-Trifluoroacetyladiamycin-14-valerate; N-Trifluoroacetyl-doxorubicin-14-valerate; Valrubicina; Valrubicine; Valrubicinum. (8S,10S)-8-Glycolyl-7,8,9,10-tetrahydro-6,8,11-trihydroxy-1-methoxy-10-[[2,3,6-trideoxy-3-(2,2,2-trifluoroacetamido)- $\alpha$ -L-lyxo-hexopyranosyl]oxy]-5,12-naphthacene-dione 8'-valerate.

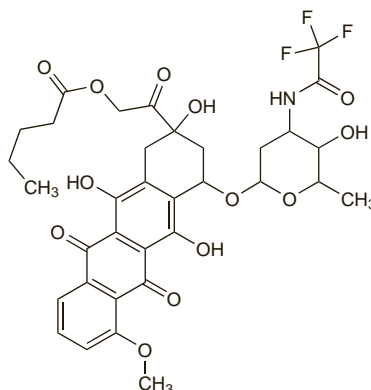
Вальрубицин

$C_{34}H_{36}F_3NO_{13} = 723.6$ .

CAS — 56124-62-0.

ATC — L01DB09.

ATC Vet — QL01DB09.



**Pharmacopoeias.** In *US*.

**USP 31** (Valrubicin). An orange to orange-red crystalline powder. Very slightly soluble in water, in hexane, and in petroleum spirit; soluble in dehydrated alcohol, in acetone, in dichloromethane, and in methyl alcohol. Store in airtight containers. Protect from light.

**Adverse Effects, Treatment, and Precautions**

Increased urinary frequency and urgency, dysuria, bladder spasm and pain may follow intravesical use of valrubicin due to local irritation of the bladder, and usually resolve within 1 to 7 days of treatment. Gross haematuria has occurred rarely but should be distinguished from drug-induced red coloration of the urine. Abdominal pain and nausea may occur.

Myelosuppression similar to that seen with other anthracyclines (see Adverse Effects of Doxorubicin, p.712) is possible if significant systemic exposure occurs. Therefore valrubicin should not be given to patients with a perforated bladder or compromised bladder mucosa.

Because of the risk of metastasis, cystectomy should be reconsidered for patients with carcinoma *in situ* who do not respond completely to valrubicin treatment after 3 months.

**Pharmacokinetics**

On intravesical use valrubicin penetrates the bladder wall but systemic absorption is low in patients who have an intact bladder mucosa. The drug is almost entirely excreted by voiding after the installation period.

**Uses and Administration**

Valrubicin is a semisynthetic analogue of the anthracycline doxorubicin (p.712). It is used for carcinoma *in situ* of the bladder (p.659) refractory to BCG vaccine, when surgery is contra-indicated, although only about 20% of such patients exhibit a complete response. A dose of 800 mg has been given intravesically once a week for 6 weeks, as 75 mL of a solution diluted with sodium chloride 0.9%. The solution should be retained for 2 hours if possible before voiding.

## ♦ References.

- Steinberg G, *et al.* Efficacy and safety of valrubicin for the treatment of Bacillus Calmette-Guérin refractory carcinoma *in situ* of the bladder. *J Urol (Baltimore)* 2000; **163**: 761-7.
- Kuznetsov DD, *et al.* Intravesical valrubicin in the treatment of carcinoma *in situ* of the bladder. *Expert Opin Pharmacother* 2001; **2**: 1009-13.

**Preparations**

**USP 31:** Valrubicin Intravesical Solution.

**Proprietary Preparations** (details are given in Part 3)

**Canad.:** Valtaxin; **Israel:** Valstar; **USA:** Valstar†.

**Verteporfin (BAN, USAN, rINN)**

Benzoporphyrin Derivative; BPD; CL-318952; Verteporfini; Verteporfina; Verteporfine; Verteporfinum. *trans*-18-Ethenyl-4,4a-dihydro-3,4-bis(methoxycarbonyl)-4a,8,14,19-tetramethyl-23H,25H-benzo[b]porphine-9,13-dipropionic acid monomethyl ester.

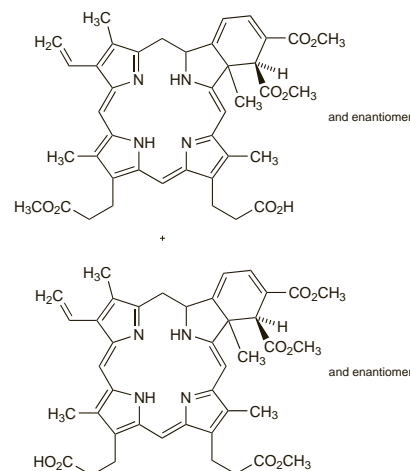
Вертепорфин

$C_{41}H_{42}N_4O_8 = 718.8$ .

CAS — 129497-78-5.

ATC — S01LA01.

ATC Vet — QS01LA01.



**Pharmacopoeias.** In *US*.

**USP 31** (Verteporfin). Store at a temperature between –25° and –10° in airtight containers.

**Adverse Effects and Precautions**

Photosensitivity will occur in all patients treated with verteporfin and patients should not be exposed to direct sunlight for 2 to 5 days after treatment. However, exposure to ambient indoor light is encouraged, as it allows gradual inactivation of any remaining drug. Headaches, injection site reactions, and visual disturbances occur frequently. Extravasation at the injection site may produce severe pain and inflammation and requires interruption of therapy. Patients who experience a severe decrease in vision should not be re-treated until their vision recovers. Other reported adverse effects include hypersensitivity, infusion-related pain (primarily presenting as back pain), chest pain, gastrointestinal disturbances, atrial fibrillation, hypertension, decreased hearing, and anaemia. Verteporfin should be used with care in patients with hepatic impairment and may be contra-indicated if impairment is severe.

**Porphyria.** The use of verteporfin is contra-indicated in patients with porphyria.

**Interactions**

Use of verteporfin with other drugs causing photosensitivity should be avoided as the reaction may be increased.

**Pharmacokinetics**

After intravenous doses, elimination of verteporfin is bi-exponential, with a terminal plasma elimination half-life of about 5 to 6 hours. Protein binding is about 90%. It is metabolised in the liver. It is excreted in faeces via the bile, mostly as unchanged drug, with less than 1% of a dose recovered in the urine.

## ♦ References.

- Houle J-M, Strong A. Clinical pharmacokinetics of verteporfin. *J Clin Pharmacol* 2002; **42**: 547-57.

## Uses and Administration

Verteporfin is a photosensitiser used in photodynamic therapy (see under Porfimer Sodium, p.764). It is used to treat neovascular (wet) age-related macular degeneration (see below). After intravenous dosage verteporfin accumulates preferentially in the endothelial cells of actively growing blood vessels, including those in the choroid. When activated by laser light it produces local vascular occlusion and this inhibits neovascularisation and reduces the decline in visual acuity. It is given by intravenous infusion over 10 minutes at a dose of 6 mg/m<sup>2</sup>. This is followed 15 minutes after the start of the infusion by activation using a laser tuned to a wavelength of 689 nanometres and delivered to the eye via a fibre optic device and a slit lamp, together with a suitable contact lens. The recommended light dose is 50 J/cm<sup>2</sup>, given over 83 seconds. Therapy may be repeated every 3 months for recurrent choroidal neovascular leakage. Verteporfin has also been investigated in the photodynamic therapy of a variety of other disorders including malignant neoplasms.

**Age-related macular degeneration.** Age-related macular degeneration (AMD) is a degenerative disease usually occurring in people over the age of 50 years.<sup>1-3</sup> The central portion of the retina (the macula) deteriorates<sup>2,4,5</sup> and it is a major cause of severe visual loss in people over 60 years old in North America and Europe.<sup>4,6</sup> There are two main types of AMD.

- In geographic atrophy or non-neovascular or non-exudative (dry) AMD, which occurs at an early stage of AMD, the retinal pigment epithelium is lost completely in localised areas, causing a gradual loss of central vision in the affected eye(s). It is characterised by retinal hypo- or hyperpigmentation, and yellow deposits of acellular amorphous debris beneath the retina, called drusen. These are usually large, or soft (with indistinct margins); small hard drusen occur naturally with ageing but, unlike drusen in AMD, do not progress.
- In neovascular or exudative (wet) AMD, new blood vessels develop in the choroidal layer beneath the retina; leaks or haemorrhage from these lead to macular oedema, retinal scarring, and often acute, significant loss of vision.<sup>2,4,5,7-10</sup> This process of choroidal neovascularisation (CNV) is defined as classic or occult according to its appearance on fluorescein angiography;<sup>2,5,9,11</sup> the classic form is associated with more rapid progression than the occult form.<sup>2,9</sup> CNV lesions are also classified according to their location relative to the fovea.<sup>1,2,12</sup> Although the neovascular form accounts for only about 20% of all cases of AMD, the risk of severe visual loss with this form is much higher than with dry AMD.<sup>1,9</sup> However, about 10 to 20% of patients with dry AMD can progress to the neovascular form,<sup>1,10</sup> and both forms can occasionally co-exist in the same patient.<sup>11</sup>

Risk factors, besides older age, include a family history of the disorder, the presence of a mutation in the complement factor H (CFH) gene, smoking, white race, and increased body-mass index;<sup>3,8,13</sup> female sex, atherosclerosis, dietary fat or fish intake, alcohol or caffeine consumption, refractive error, iris colour, and increased exposure to sunlight have also been proposed as risk factors but have not consistently been related to development of AMD.<sup>13</sup>

There is currently no treatment that effectively prevents visual loss or improves vision in all patients with AMD.<sup>14</sup>

- Laser photocoagulation treatment is of proven efficacy for neovascular AMD, especially for extrafoveal CNV; however, rates of recurrence are high.<sup>1,6,8,13,14</sup>
- Photodynamic therapy (see under Porfimer Sodium, p.764) with verteporfin has been shown to decrease the risk of visual loss in patients with neovascular AMD, including subfoveal CNV.<sup>1,4,8,9,11,12,14-18</sup> Systematic reviews have noted that although photodynamic therapy with verteporfin is probably effective in preventing visual loss in those with classic and occult CNV due to AMD, the size of the effect remains in doubt.<sup>5,19</sup> Furthermore, the therapy can only be effective during the proliferative stage of the disease while the neovascular process is active.<sup>5</sup>

In the UK, NICE guidelines considered the evidence to show a larger treatment effect in patients with classic CNV, and recommend photodynamic therapy in those patients with neovascular AMD with a confirmed diagnosis of classic, with no occult, subfoveal CNV.<sup>2</sup> However, other guidelines<sup>20</sup> on the use of verteporfin recommend that verteporfin treatment be considered for patients with minimally classic subfoveal CNV who have relatively small lesions, or where the proportion of classic CNV is increasing. For those patients with occult CNV and who are presumed to have recent disease progression, verteporfin may be considered in those with smaller lesions or lower levels of visual acuity; for those with large occult le-

sions, treatment may be considered if levels of visual acuity are rapidly decreasing. Patients should be followed up at least as often as every 3 months after initial therapy, and re-treated if necessary.<sup>20</sup>

While photodynamic therapy is considered to have minimal adverse effects and a low complication rate, some have cautioned that patients should be counselled that verteporfin therapy rarely leads to an improvement in vision.<sup>21</sup>

- Vascular endothelial growth factor (VEGF) plays a role in the development of CNV secondary to AMD; pegaptanib and ranibizumab are VEGF inhibitors used in the treatment of neovascular (wet) AMD.<sup>22-24</sup> Systematic reviews<sup>5,26</sup> of randomised controlled studies of these drugs concluded that both show benefit in slowing or stopping the progression of disease. Greater effect was seen with ranibizumab than with pegaptanib, although head-to-head comparative studies are needed to confirm this. Bevacizumab has also been tried, although its use is controversial.<sup>6,22,27</sup> Triamcinolone acetonide, a corticosteroid that may also downregulate VEGF, has been given intravitreally with variable results; combination treatment with photodynamic therapy is under investigation.<sup>10,13,28</sup>
  - Angiogenesis inhibitors such as anecortave are under investigation for neovascular AMD.<sup>3,10,13,14,28</sup> Interferon alfa showed encouraging preliminary results, but controlled data showed no benefit.<sup>8,10,13</sup> Thalidomide has been tried, but trials were stopped due to adverse effects.<sup>10,13</sup>
  - Vitamin and mineral supplements may be of use in selected patients; the AREDS trial found that antioxidants (vitamin C, vitamin E, and beta-carotene) plus zinc modestly benefited those with moderate to severe signs of the disease.<sup>11,14</sup> However, beta-carotene should be avoided in smokers.<sup>3,6,10</sup> The carotenoids, lutein and zeaxanthin, have been promoted as retinal protectants, but controlled data are lacking.<sup>10,11,14,29</sup> Some recommend that those at risk of AMD should be encouraged to stop smoking and to consume a diet including vegetables, fish, nuts, and to reduce consumption of fats especially vegetable oil.<sup>7,29</sup> A prospective cohort study found that a high dietary intake of vitamin E and zinc, or an above-median intake of the combination of vitamins C and E, beta-carotene, and zinc were associated with a lower risk of incident AMD.<sup>30</sup> However, systematic reviews<sup>31,32</sup> have found no evidence to support the role of antioxidant vitamin and mineral supplements in the primary prevention of AMD.
  - Retinal or macular surgery, and transpupillary thermotherapy are under investigation.<sup>1,8,11,13,14,28</sup> Radiotherapy has also been tried with mixed results.<sup>10,13</sup> Retinal transplantation is under investigation.<sup>6,8,11,14</sup> Gene silencing with bevasiranib, a short interfering RNA (siRNA) therapeutic designed to turn off or silence the gene that produces VEGF, is also under investigation for wet AMD.<sup>33</sup>
- Soubrane G, Bressler NM. Treatment of subfoveal choroidal neovascularisation in age related macular degeneration: focus on clinical application of verteporfin photodynamic therapy. *Br J Ophthalmol* 2001; **85**: 483-95.
  - NICE. Guidance on the use of photodynamic therapy for age-related macular degeneration: Technology Appraisal 68 (issued September 2003). Available at: [http://www.nice.org.uk/nicemedia/pdf/68\\_PDTGuidance.pdf](http://www.nice.org.uk/nicemedia/pdf/68_PDTGuidance.pdf) (accessed 09/05/08)
  - El-Amir AN, et al. Age-related macular degeneration. *Br J Hosp Med* 2005; **66**: 677-81.
  - Messmer KJ, Abel SR. Verteporfin for age-related macular degeneration. *Ann Pharmacother* 2001; **35**: 1593-8.
  - Wormald R, et al. Photodynamic therapy for neovascular age-related macular degeneration. Available in The Cochrane Database of Systematic Reviews; Issue 3. Chichester: John Wiley; 2007 (accessed 01/08/08).
  - Cook HL, et al. Age-related macular degeneration: diagnosis and management. *Br Med Bull* 2008; **85**: 127-49.
  - Constable IJ. Age-related macular degeneration and its possible prevention. *Med J Aust* 2004; **181**: 471-2.
  - Fine SL, et al. Age-related macular degeneration. *N Engl J Med* 2000; **342**: 483-92.
  - Yang YC. Preserving vision with verteporfin photodynamic therapy. *Hosp Med* 2004; **65**: 39-43.
  - Comer GM, et al. Current and future treatment options for non-exudative and exudative age-related macular degeneration. *Drugs Aging* 2004; **21**: 967-92.
  - Bylsma GW, Guymer RH. Treatment of age-related macular degeneration. *Clin Exp Optom* 2005; **88**: 322-34.
  - Treatment of age-related macular degeneration with photodynamic therapy (TAP) Study Group. Photodynamic therapy of subfoveal choroidal neovascularization in age-related macular degeneration with verteporfin: one-year results of 2 randomized clinical trials—TAP report 1. *Arch Ophthalmol* 1999; **117**: 1329-45.
  - Sun JK, Miller JW. Medical treatment of choroidal neovascularization secondary to age-related macular degeneration. *Int Ophthalmol Clin* 2005; **45**: 115-32.
  - Lois N. Neovascular age-related macular degeneration. *Compr Ophthalmol Update* 2004; **5**: 143-61.
  - Blumenkrantz MS, et al. Verteporfin therapy for subfoveal choroidal neovascularization in age-related macular degeneration: three-year results of an open-label extension of 2 randomized clinical trials—TAP report no. 5. *Arch Ophthalmol* 2002; **120**: 1307-14.
  - Blinder KJ, et al. Verteporfin therapy of subfoveal choroidal neovascularization in pathologic myopia: 2-year results of a randomized clinical trial—VIP report no. 3. *Ophthalmology* 2003; **110**: 667-73.

- Keam SJ, et al. Verteporfin: a review of its use in the management of subfoveal choroidal neovascularisation. *Drugs* 2003; **63**: 2521-54.
- Wickens J, Blinder KJ. A preliminary benefit-risk assessment of verteporfin in age-related macular degeneration. *Drug Safety* 2006; **29**: 189-99.
- Meads C, Hyde C. Photodynamic therapy with verteporfin is effective, but how big is its effect? Results of a systematic review. *Br J Ophthalmol* 2004; **88**: 212-17.
- Verteporfin Roundtable Participants. Guidelines for using verteporfin (Visudyne) in photodynamic therapy for choroidal neovascularization due to age-related macular degeneration and other causes: update. *Retina* 2005; **25**: 119-34.
- Sternberg P, Lewis H. Photodynamic therapy for age-related macular degeneration: a candid appraisal. *Am J Ophthalmol* 2004; **137**: 483-5.
- Anonymous. A view on new drugs for macular degeneration. *Drug Ther Bull* 2007; **45**: 49-52.
- Rosenfeld PJ, et al. MARINA Study Group. Ranibizumab for neovascular age-related macular degeneration. *N Engl J Med* 2006; **355**: 1419-31.
- Brown DM, et al. ANCHOR Study Group. Ranibizumab versus verteporfin for neovascular age-related macular degeneration. *N Engl J Med* 2006; **355**: 1432-44.
- Takeda AL, et al. Pegaptanib and ranibizumab for neovascular age-related macular degeneration: a systematic review. *Br J Ophthalmol* 2007; **91**: 1177-82.
- Vedula SS, Krzystolik MG. Antiangiogenic therapy with anti-vascular endothelial growth factor modalities for neovascular age-related macular degeneration. Available in The Cochrane Database of Systematic Reviews; Issue 2. Chichester: John Wiley; 2008 (accessed 09/05/08).
- Wong TY, et al. Clinical update: new treatments for age-related macular degeneration. *Lancet* 2007; **370**: 204-6.
- Liu M, Regillo CD. A review of treatments for macular degeneration: a synopsis of currently approved treatments and ongoing clinical trials. *Curr Opin Ophthalmol* 2004; **15**: 221-6.
- Anonymous. Nutritional supplements for macular degeneration. *Drug Ther Bull* 2006; **44**: 9-11.
- van Leeuwen R, et al. Dietary intake of antioxidants and risk of age-related macular degeneration. *JAMA* 2005; **294**: 3101-7.
- Chong EW-T, et al. Dietary antioxidants and primary prevention of age related macular degeneration: systematic review and meta-analysis. *BMJ* 2007; **335**: 755-9.
- Evans JR, Henshaw K. Antioxidant vitamin and mineral supplements for preventing age-related macular degeneration. Available in The Cochrane Database of Systematic Reviews; Issue 1. Chichester: John Wiley; 2008 (accessed 09/05/08).
- Arjamaa O. Gene silencing in wet age-related macular degeneration. *Lancet* 2006; **368**: 630-1.

## Preparations

**USP 31:** Verteporfin for Injection.

**Proprietary Preparations** (details are given in Part 3)

**Arg:** Visudyne; **Austral:** Visudyne; **Austria:** Visudyne; **Belg:** Visudyne; **Braz:** Visudyne; **Canada:** Visudyne; **Chile:** Visudyne; **Cz:** Visudyne; **Denm:** Visudyne; **Fin:** Visudyne; **Fr:** Visudyne; **Ger:** Visudyne; **Gr:** Visudyne; **Hong Kong:** Visudyne; **Hung:** Visudyne; **India:** Visudyne; **Israel:** Visudyne; **Ital:** Visudyne; **Jpn:** Visudyne; **Malaysia:** Visudyne; **Neth:** Visudyne; **Norw:** Visudyne; **NZ:** Visudyne; **Philipp:** Visudyne; **Pol:** Visudyne; **Port:** Visudyne; **Rus:** Visudyne (Визудин); **S.Afr:** Visudyne; **Singapore:** Visudyne; **Spain:** Visudyne; **Swed:** Visudyne; **Switz:** Visudyne; **Thai:** Visudyne; **Turk:** Visudyne; **UK:** Visudyne; **USA:** Visudyne; **Venez:** Visudyne.

## Vinblastine Sulfate (USAN, rINN)

29060-LE; NSC-49842; Sulfato de Vinblastina; Sulfato de vinblastina; Vinblastinisulfatti; Vinblastin Sulfat; Vinblastine, sulfate de; Vinblastine Sulphate (BANM); Vinblastini sulfas; Vinblastino sulfatas; Vinblastinsulfat; Vinblastin-sulfat; Vinblastin-sulfat; Vinca-leukoblastine Sulphate; VLB (vinblastine); Winblastyny siarcczan.

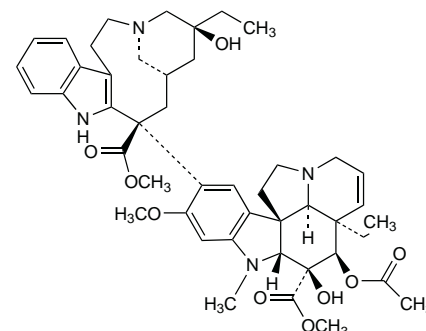
Винбластина Сульфат

$C_{46}H_{58}N_4O_9 \cdot H_2SO_4 = 909.1$ .

**CAS** — 865-21-4 (vinblastine); 143-67-9 (vinblastine sulfate).

**ATC** — L01CA01.

**ATC Vet** — QL01CA01.



(vinblastine)