

Omeprazole (BAN, USAN, rINN)

H-168/68; Omepratsoli; Omeprazol; Omeprazolas; Oméprazole; Omeprazolium. (R_S)-5-Methoxy-2-(4-methoxy-3,5-dimethyl-2-pyridylmethylsulphonyl)benzimidazole.

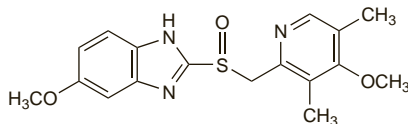
Омепразол

C₁₇H₁₉N₃O₅S = 345.4.

CAS — 73590-58-6.

ATC — A02BC01.

ATC Vet — QA02BC01.



Pharmacopoeias. In *Chin.*, *Eur.* (see p.vii), and *US*.

Ph. Eur. 6.2 (Omeprazole). A white or almost white powder. It exhibits polymorphism. Very slightly soluble in water; sparingly soluble in alcohol and in methyl alcohol; soluble in dichloromethane. It dissolves in dilute solutions of alkali hydroxides. Store in airtight containers at a temperature between 2° and 8°. Protect from light.

USP 31 (Omeprazole). A white to off-white powder. Very slightly soluble in water; sparingly soluble in alcohol and in methyl alcohol; soluble in dichloromethane. Store in airtight containers at a temperature not exceeding 8°. Protect from moisture.

Omeprazole Magnesium (BANM, USAN, rINN)

Magnesi Omeprazolium; Omeprazol magnésico; Oméprazole magnésique; Oméprazole Magnésique; Omeprazolium magnesium.

Магния Омепразол

C₃₄H₃₆MgN₆O₁₀S₂ = 713.1.

CAS — 95382-33-5.

ATC — A02BC01.

ATC Vet — QA02BC01.

Pharmacopoeias. In *US*.

USP 31 (Omeprazole Magnesium). A white to off-white powder. Very soluble in water and in dichloromethane; slightly soluble in alcohol; sparingly soluble in methyl alcohol. Store in airtight containers. Protect from light.

Omeprazole Sodium (BANM, USAN, rINN)

Natrii Omeprazolium; Omepratsolinatrium; Omeprazol sódico; Omeprazol sodná sůl monohydrát; Oméprazole sodique; Omeprazolnatrium; Omeprazol-nátrium; Omeprazol natrio druska; Omeprazolium natrium; Omeprazolium Natrium Monohydricum.

Натрий Омепразол

C₁₇H₁₈N₃NaO₅S = 367.4.

CAS — 95510-70-6.

ATC — A02BC01.

ATC Vet — QA02BC01.

Pharmacopoeias. In *Eur.* (see p.vii).

Ph. Eur. 6.2 (Omeprazole Sodium). A white or almost white, hygroscopic powder. Freely soluble in water and in alcohol; very slightly soluble in dichloromethane; soluble in propylene glycol. The pH of a 2% solution in water is 10.3 to 11.3. Store in airtight containers. Protect from light.

Adverse Effects

Proton pump inhibitors are generally well tolerated, and adverse effects are relatively infrequent. The adverse effects reported most often with omeprazole and other proton pump inhibitors have been headache, diarrhoea, and skin rashes; they have sometimes been severe enough to require stopping treatment. Other effects include pruritus, dizziness, fatigue, constipation, nausea and vomiting, flatulence, abdominal pain, arthralgia and myalgia, urticaria, and dry mouth. Isolated cases of photosensitivity, bullous eruption, erythema multiforme, Stevens-Johnson syndrome, and toxic epidermal necrolysis have occurred. Hypersensitivity reactions, including fever, bronchospasm, angioedema, and anaphylaxis have been reported. Effects on the CNS include occasional insomnia, somnolence, and vertigo; reversible confusional states, agitation, depression, and hallucinations have occurred in severely ill patients. Raised liver enzymes, and isolated cases of hepatitis, jaundice, hepatic failure, and hepatic encephalopathy, have been reported. Other adverse effects reported rarely include paraesthesia, blurred vision, alopecia, stomatitis, increased sweating, taste

disturbances, peripheral oedema, malaise, hyponatraemia, blood disorders (including agranulocytosis, leucopenia, and thrombocytopenia), gynaecomastia, impotence, and interstitial nephritis.

Proton pump inhibitors may increase the risk of gastrointestinal infections because of their acid suppressive effects.

Early toxicological studies identified carcinoid-like tumours of the gastric mucosa in *rats* given very high doses of omeprazole over long periods; this is reviewed in more detail under Gastrointestinal Tumours, below.

Incidence of adverse effects. Prescription-event monitoring for 16 205 patients prescribed omeprazole, 17 329 prescribed lansoprazole, and 11 541 prescribed pantoprazole indicated that adverse events were reported infrequently, with the most common being gastrointestinal disturbances and headache. The incidences of diarrhoea, the most commonly reported event, per 1000 days of exposure, were 0.18 for omeprazole, 0.39 for lansoprazole, and 0.23 for pantoprazole. Despite the inherent biases of such a cohort study, there did seem to be some evidence that lansoprazole might be associated with a somewhat greater risk of diarrhoea, particularly in the elderly.¹

1. Martin RM, *et al.* The rates of common adverse events reported during treatment with proton pump inhibitors used in general practice in England: cohort studies. *Br J Clin Pharmacol* 2000; **50**: 366–72.

Effects on the blood. There have been rare cases of leucopenia, agranulocytosis, thrombocytopenia, and pancytopenia, with omeprazole and other proton pump inhibitors such as lansoprazole and pantoprazole.^{1,3} Auto-immune haemolytic anaemia has also been reported with omeprazole.⁴

1. Holt TL, *et al.* Neutropenia associated with omeprazole. *Med J Aust* 1999; **170**: 141–2.
2. Zlabek JA, Anderson CG. Lansoprazole-induced thrombocytopenia. *Ann Pharmacother* 2002; **36**: 809–11.
3. Watson TD, *et al.* Pantoprazole-induced thrombocytopenia. *Ann Pharmacother* 2006; **40**: 758–61.
4. Butt ML, *et al.* Autoimmune haemolytic anaemia associated with use of omeprazole. *Br J Hosp Med* 2007; **68**: 108.

Effects on the cardiovascular system. Results and preliminary analyses from 2 studies raised concerns about a possible increased risk of myocardial infarction, cardiac failure, and cardiac-related sudden death in patients taking omeprazole or esomeprazole compared with patients who received surgery for gastro-oesophageal reflux disease.^{1,2} However, an FDA safety review found that patients who underwent surgery tended to be younger and less likely to have a history of cardiac problems or cardiac risk factors than those treated with one of the drugs.² The FDA concluded that long-term use of these drugs is not likely to be associated with an increased risk of cardiac problems.³ However, while Health Canada⁴ considered that there was no evidence to support such an increased risk with long-term use of esomeprazole they were unable to make such a definitive conclusion for omeprazole.

1. FDA. Early communication about an ongoing safety review: omeprazole (Prilosec) esomeprazole (Nexium) (issued 9th August 2007). Available at: http://www.fda.gov/cder/drug/early_comm/omeprazole_esomeprazole.htm (accessed 28/01/08)
2. FDA. Follow-up to the August 9, 2007, communication about the ongoing safety review of omeprazole and esomeprazole (issued 10th December 2007). Available at: http://www.fda.gov/cder/drug/early_comm/omeprazole_esomeprazole_update.htm (accessed 28/01/08)
3. FDA. FDA's safety reviews of Prilosec and Nexium find no evidence of increased rates of cardiac events (issued 10th December 2007). Available at: <http://www.fda.gov/bbs/topics/NEWS/2007/NEW01754.html> (accessed 28/01/08)
4. Health Canada. Health Canada completes safety review of Losec (omeprazole) and Nexium (esomeprazole) (issued 27 February 2008). Available at: http://www.hc-sc.gc.ca/ahc-asc/media/advisories-avis/_2008/2008_34-eng.php (accessed 09/07/08)

Effects on the endocrine system. Up to December 1991, WHO had received 30 reports of impotence or gynaecomastia which might have been due to omeprazole;¹ of these reports 15 were of impotence, 13 of gynaecomastia in men, and 2 of breast enlargement in women. The Spanish Pharmacovigilance System reported 24 cases of gynaecomastia in association with use of proton pump inhibitors, including lansoprazole and rabeprazole, between January 1982 and July 2006. In most of the cases, gynaecomastia improved after stopping the drug.² For reference to a case-control study showing no statistical link between gynaecomastia and omeprazole, see under Cimetidine, p.1717.

1. Lindquist M, Edwards IR. Endocrine adverse effects of omeprazole. *BMJ* 1992; **305**: 451–2.
2. Carvajal A, *et al.* Gynaecomastia associated with proton pump inhibitors: a case series from the Spanish Pharmacovigilance System. *Drug Safety* 2007; **30**: 527–31.

Effects on the eyes. Visual disturbances associated with the use of omeprazole have included 6 cases of irreversible blindness or visual impairment in severely ill patients given the drug intravenously, and 13 cases of visual disturbances associated with oral use.¹ As a result of concern about these effects the availability of intravenous omeprazole was restricted in Germany; however, the consensus appears to be that a causal link has not been

established between omeprazole and these ocular effects. Suggestions that visual (and also auditory²) impairment could follow drug-induced vasculitis^{2,4} appear to be contentious.^{1,5,7} A cohort study involving 140 128 patients receiving antiseecretory therapy, 33 988 of whom received omeprazole, found no evidence that any of the drugs used was associated with a major increase in risk of vascular or inflammatory disorders of the eye;⁸ however, the statistical power of this study was not high.⁹

1. Creutzfeldt WC, Blum AL. Safety of omeprazole. *Lancet* 1994; **343**: 1098.
2. Schönhöfer PS. Intravenous omeprazole and blindness. *Lancet* 1994; **343**: 665.
3. Schönhöfer PS. Safety of omeprazole and lansoprazole. *Lancet* 1994; **343**: 1369–70.
4. Schönhöfer PS, *et al.* Ocular damage associated with proton pump inhibitors. *BMJ* 1997; **314**: 1805.
5. Colin-Jones D. Safety of omeprazole and lansoprazole. *Lancet* 1994; **343**: 1369.
6. Lessell S. Omeprazole and ocular damage. *BMJ* 1998; **316**: 67.
7. Sachs G. Omeprazole and ocular damage. *BMJ* 1998; **316**: 67–8.
8. García Rodríguez LA, *et al.* A cohort study of the ocular safety of anti-ulcer drugs. *Br J Clin Pharmacol* 1996; **42**: 213–16.
9. Merlo J, Ransam J. Ocular safety of anti-ulcer drugs. *Br J Clin Pharmacol* 1997; **43**: 449.

Effects on the kidneys. Acute interstitial nephritis developed in 2 elderly patients given omeprazole for the treatment of gastro-oesophageal reflux disease.^{1,2} When the drug was stopped, renal function improved rapidly in 1 patient, but recurred upon rechallenge,¹ while in the other renal function remained severely affected for several months.² It was postulated that this adverse effect might have an allergic mechanism.² In these cases interstitial nephritis was associated with rash and eosinophilia; however, a further 2 cases of acute interstitial nephritis associated with omeprazole therapy in elderly patients^{3,4} did not exhibit these symptoms. In another report, associated rash without eosinophilia was seen.⁵

The Australian Adverse Drug Reactions Advisory Committee (ADRAC)⁶ stated in April 2003 that it had received 18 biopsy-confirmed reports of interstitial nephritis associated with the use of omeprazole. These patients had presented with symptoms including weight loss, malaise, fever, and nausea; polyuria and polydipsia occurred in one case. Most patients had raised plasma-urea and/or plasma-creatinine concentrations. ADRAC had also received 2 reports of interstitial nephritis associated with rabeprazole.⁶ A case report (in March 2005) of 2 cases of interstitial nephritis associated with the omeprazole isomer esomeprazole noted that, by October 2004, the manufacturer had reported being aware of some 15 cases worldwide possibly associated with the drug, and at least 200 associated with omeprazole.⁷ Acute interstitial nephritis has also been associated with the use of pantoprazole in an elderly woman for the treatment of gastro-oesophageal reflux disease.⁸

1. Ruffenach SJ, *et al.* Acute interstitial nephritis due to omeprazole. *Am J Med* 1992; **93**: 472–3.
2. Christensen PB, *et al.* Renal failure after omeprazole. *Lancet* 1993; **341**: 55.
3. Assouad M, *et al.* Recurrent acute interstitial nephritis on rechallenge with omeprazole. *Lancet* 1994; **344**: 549.
4. Jones B, *et al.* Acute interstitial nephritis due to omeprazole. *Lancet* 1994; **344**: 1017–18.
5. Kuiper JJ. Omeprazole-induced acute interstitial nephritis. *Am J Med* 1993; **95**: 248.
6. Adverse Drug Reactions Advisory Committee (ADRAC). Interstitial nephritis with the proton pump inhibitors. *Aust Adverse Drug React Bull* 2003; **22**: 3. Also available at: <http://www.tga.health.gov.au/adra/aadr/aadr304.htm> (accessed 07/05/04)
7. Geevasinga N, *et al.* Acute interstitial nephritis secondary to esomeprazole. *Med J Aust* 2005; **182**: 235–6.
8. Ra A, Tobe SW. Acute interstitial nephritis due to pantoprazole. *Ann Pharmacother* 2004; **38**: 41–5.

Effects on the liver. Raised liver enzymes have occurred with omeprazole and other proton pump inhibitors, and there have been isolated cases of hepatotoxicity. For a study suggesting a relatively low incidence of acute liver injury in patients receiving omeprazole see Cimetidine, p.1717.

References

1. Jochem V, *et al.* Fulminant hepatic failure related to omeprazole. *Am J Gastroenterol* 1992; **87**: 523–5.
2. Kourg SI, *et al.* Omeprazole and the development of acute hepatitis. *Eur J Emerg Med* 1998; **5**: 467–9.

Effects on the musculoskeletal system. Progressive muscular weakness suggestive of myopathy developed in a 78-year-old patient given oral omeprazole.¹ After 4 weeks of treatment the patient required assistance in walking and rising from squatting. Weakness resolved on withdrawal of the drug, but returned on rechallenge. Acute myopathy has also been reported after a single infusion of omeprazole.² Analysis of the WHO adverse drug reaction database in March 2005 revealed 868 reports associating proton pump inhibitors with myalgia, of which 292 cases had symptoms indicative of muscle disorders including polymyositis and rhabdomyolysis.³ Reports implicated omeprazole, pantoprazole, lansoprazole, esomeprazole, and rabeprazole, and it was suggested that myopathy was probably a class effect. The mechanism might involve induction of auto-immune antibodies. A report of 5 cases of arthralgia, sometimes associated with swelling of the affected joints, in patients receiving omeprazole,⁴ also noted that some reported cases of omeprazole-associated headache were accompanied by arthralgia or myalgia. In another case⁵ arthralgia in a patient with a hereditary myopathy receiving