

common practice to give 2 or 3 injections of suramin or pentamidine before starting melarsoprol therapy.

The greatest risk is from reactive encephalopathy which occurs in about 10% of patients treated with melarsoprol and is usually seen between the end of the first 3- or 4-day course of injections and the start of the second course. Encephalopathy may be sudden in onset or develop slowly. Symptoms include fever, headache, tremor, slurring of speech, convulsions, and coma; death has occurred in up to 5% of patients treated with melarsoprol. Less commonly, haemorrhagic encephalopathy may occur. The prophylactic use of corticosteroids has been suggested during treatment courses of melarsoprol (see African Trypanosomiasis, below). Treatment of reactive encephalopathy has included the use of corticosteroids, hypertonic solutions to combat cerebral oedema, anticonvulsants such as diazepam, and subcutaneous adrenaline; dimercaprol has been given on the assumption that encephalopathy resulted from arsenic poisoning, but has not generally been of benefit.

Hypersensitivity reactions to melarsoprol may occur during the second and subsequent courses of treatment. Desensitisation with gradually increasing doses of melarsoprol has been attempted; corticosteroids may help to control symptoms during this procedure. Some authorities consider that the use of small doses of melarsoprol may increase the risk of resistance.

Melarsoprol injection is very irritant and extravasation during intravenous use should be avoided. Vomiting and abdominal colic may occur if it is injected too rapidly. Other adverse effects reported include agranulocytosis, hypertension, peripheral neuropathy, proteinuria, severe diarrhoea, myocardial damage, exfoliative dermatitis, and hepatic disturbances.

References.

1. Pepin J, *et al.* Trial of prednisolone for prevention of melarsoprol-induced encephalopathy in gambiense sleeping sickness. *Lancet* 1989; **i**: 1246-50.
2. Pepin J, Milord F. African trypanosomiasis and drug-induced encephalopathy: risk factors and pathogenesis. *Trans R Soc Trop Med Hyg* 1991; **85**: 222-4.
3. Pepin J, *et al.* Risk factors for encephalopathy and mortality during melarsoprol treatment of *Trypanosoma brucei gambiense* sleeping sickness. *Trans R Soc Trop Med Hyg* 1995; **89**: 92-7.

Precautions

Use of melarsoprol in febrile patients has been associated with an increased incidence of reactive encephalopathy, and therefore it should not be given during epidemics of influenza. Intercurrent infections such as malaria and pneumonia should be treated before melarsoprol is used. Severe haemolytic reactions have been reported in patients with G6PD deficiency. It may precipitate erythema nodosum when given to patients with leprosy.

Patients should be in hospital when they are treated with melarsoprol and dosage decided after taking into account their general condition.

Treatment of pregnant women with trypanosomiasis should be deferred until after delivery. Pregnant women with meningoencephalitis may be treated with pentamidine (*Trypanosoma brucei gambiense*) or suramin (*T. b. rhodesiense*).

Pharmacokinetics

Melarsoprol is reported to be unreliably absorbed if given orally and is usually given by intravenous injection. A small amount penetrates into the CSF where it has a local trypanocidal action. It is rapidly metabolised and excreted in the faeces and urine so any prophylactic effect is short-lived.

Uses and Administration

Melarsoprol, a trivalent arsenical derivative, is a trypanocide which appears to act by inhibiting trypanosomal pyruvate kinase. It is effective in the treatment of all stages of African trypanosomiasis due to *Trypanosoma brucei gambiense* or *T. brucei rhodesiense*, but because of its toxicity its use is usually re-

served for stages of the disease involving the CNS. Resistance has been reported to develop.

Patients undergoing therapy with melarsoprol should be treated in hospital. Melarsoprol is given by intravenous injection as a 3.6% solution in propylene glycol. The injection should be given slowly, care being taken to prevent leakage into the surrounding tissues, and the patient should remain supine and fasting for several hours after the injection.

Treatment protocols vary, but in general melarsoprol is given in low doses initially, especially in children and debilitated patients, increased gradually to the maximum daily dose of 3.6 mg/kg. Doses are given daily for 3 or 4 days and the course repeated 2 or 3 times with an interval of 7 to 10 days between courses. Since massive destruction of parasites resulting in a Jarisch-Herxheimer reaction is particularly dangerous during treatment with melarsoprol, several doses of suramin or pentamidine may be given to induce the reaction before melarsoprol is started.

Melarsoprol potassium is a water-soluble derivative of melarsoprol which was formerly used as an alternative to melarsoprol but was probably more toxic and less effective.

African trypanosomiasis. Melarsoprol, which is effective against both *Trypanosoma brucei gambiense* and *T. b. rhodesiense*, is usually only given to treat the meningoencephalitic stage of African trypanosomiasis (p.827) because it may produce potentially fatal encephalopathy. However, protection against this toxicity may be provided by prophylaxis with prednisolone.^{1,2} Therapy with melarsoprol and eflornithine was reported to be effective in a patient who had not responded to either drug alone.³ A comparative study⁴ in 500 patients with second-stage infection with *T. b. gambiense* found that a more concise dosage regimen of melarsoprol 2.2 mg/kg daily, as a single course over 10 days, was similar in efficacy to standard regimens of 1.2 to 3.6 mg/kg daily for 3 or 4 days repeated twice over a 26-day period with 7-day intervals between series, although there was no difference between the regimens in the incidence of associated encephalopathy.

1. Pepin J, *et al.* Trial of prednisolone for prevention of melarsoprol-induced encephalopathy in gambiense sleeping sickness. *Lancet* 1989; **i**: 1246-50.
2. Pepin J, *et al.* Risk factors for encephalopathy and mortality during melarsoprol treatment of *Trypanosoma brucei gambiense* sleeping sickness. *Trans R Soc Trop Med Hyg* 1995; **89**: 92-7.
3. Simarro PP, Asumu PN. Gambian trypanosomiasis and synergism between melarsoprol and eflornithine: first case report. *Trans R Soc Trop Med Hyg* 1996; **90**: 315.
4. Burri C, *et al.* Efficacy of new, concise schedule for melarsoprol in treatment of sleeping sickness caused by *Trypanosoma brucei gambiense*: a randomised trial. *Lancet* 2000; **355**: 1419-25.

Mepacrine Hydrochloride (BANM, dINNM)

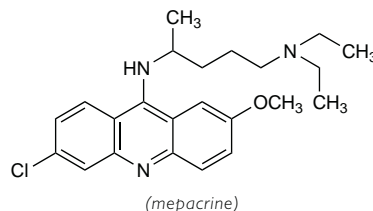
Acridinum; Acrinamine; Antimalarinae Chlorhydras; Chinacrina; Hydrochloruro de mepacrina; Mépacrine, Chlorhydrate de; Mepacrin Hydrochloridum; Mepakrin Hidroklorür; Quinacrine Hydrochloride. 6-Chloro-9-(4-diethylamino-1-methylbutylamino)-2-methoxyacridine dihydrochloride dihydrate.

Мепакрина Гидрохлорид

$C_{23}H_{30}ClN_3O_2 \cdot 2HCl \cdot 2H_2O = 508.9$.

CAS — 83-89-6 (mepacrine); 69-05-6 (anhydrous mepacrine dihydrochloride); 6151-30-0 (mepacrine dihydrochloride dihydrate).

ATC — P01AX05.



Adverse Effects

The most common adverse effects associated with mepacrine are dizziness, headache, and gastrointestinal disturbances such as nausea and vomiting. Reversible yellow discoloration of the skin, conjunctiva, and urine may occur during long-term use or after large doses; blue/black discoloration of the palate and discoloration of the nails have also been reported. Doses such as those used in the treatment of giardiasis may occasionally cause transient acute toxic psychosis and CNS stimulation. Convulsions have been reported at high doses. Ocular toxicity similar to

that seen with chloroquine (p.600) and chronic dermatoses, including severe exfoliative dermatitis and lichenoid eruptions, have also occurred after prolonged use of mepacrine. Hepatotoxicity and aplastic anaemia occur rarely.

Effects on the nervous system. Two patients had convulsions a few hours after mepacrine hydrochloride 400 mg was given intrapleurally for malignant effusions. One developed status epilepticus and died and the other was successfully treated with anticonvulsants.¹

1. Borda I, Krant M. Convulsions following intrapleural administration of quinacrine hydrochloride. *JAMA* 1967; **201**: 1049-50.

Precautions

Mepacrine should be used with caution in elderly patients or patients with a history of psychosis, or in the presence of hepatic disease. Mepacrine can cause exacerbation of psoriasis and should be avoided in psoriatic patients.

Porphyria. Mepacrine should be used with caution in patients with porphyria.

Interactions

Mepacrine has been reported to produce a mild disulfiram-like reaction (see p.2296) when taken with alcohol.

Theoretically, mepacrine may increase the plasma concentrations of primaquine resulting in a higher risk of toxicity, and it has been recommended that these drugs should not be used together.

Pharmacokinetics

Mepacrine is readily absorbed from the gastrointestinal tract and widely distributed throughout the body. It accumulates in body tissues, particularly the liver, and is liberated slowly. It is excreted slowly mainly in the urine, and is still detectable in the urine after 2 months. Mepacrine crosses the placenta.

Intrapleural administration. Peak plasma concentrations of mepacrine far above those associated with CNS effects were rapidly attained in 3 of 4 patients after intrapleural instillation of a solution of mepacrine hydrochloride and remained at these levels for several hours.¹

1. Björkman S, *et al.* Pharmacokinetics of quinacrine after intrapleural instillation in rabbits and man. *J Pharm Pharmacol* 1989; **41**: 160-73.

Uses and Administration

Mepacrine is a 9-aminoacridine antiprotozoal used as the hydrochloride mainly as an alternative to the nitroimidazoles in the treatment of giardiasis (p.824).

In giardiasis, mepacrine hydrochloride is given orally in doses of 100 mg three times daily after food for 5 to 7 days. A dose for children is 2 mg/kg given three times daily (maximum 300 mg daily).

Mepacrine hydrochloride may also be used, alone or with hydroxychloroquine, for the treatment of discoid and subcutaneous lupus erythematosus. It has also been used locally in the treatment of some forms of cutaneous leishmaniasis, as a sterilisation technique for contraception, and in the management of malignant effusions. It was formerly used to treat malaria.

The mesilate was also formerly used.

Mepacrine is under investigation for the treatment of variant Creutzfeldt-Jakob Disease.

Contraception. Sterilisation with intra-uterine mepacrine has been attempted as an irreversible method of contraception (p.2070). It produces occlusion of the fallopian tube and has been reported to be an effective nonsurgical means of female sterilisation,¹ although it may be less effective than other methods.² There has been speculation about the risk of cancer from this technique but there appeared to be no evidence to confirm such a risk.^{3,5} However, the method remains controversial and a full evaluation of its safety and efficacy has been recommended.⁶ The Indian government has banned the use of mepacrine for sterilisation.

1. Hieu DT, *et al.* 31 781 Cases of non-surgical female sterilisation with quinacrine pellets in Vietnam. *Lancet* 1993; **342**: 213-17.
2. Sokal DC, *et al.* Contraceptive effectiveness of two insertions of quinacrine: results from 10-year follow-up in Vietnam. *Contraception* 2008; **78**: 61-5.
3. Anonymous. Death of a study: WHO, what, and why. *Lancet* 1994; **343**: 987-8.
4. Hieu DT. Quinacrine method of family planning. *Lancet* 1994; **343**: 1040.
5. Sokal DC, *et al.* Safety of quinacrine contraceptive pellets: results from 10-year follow-up in Vietnam. *Contraception* 2008; **78**: 66-72.
6. Benagiano G. Sterilisation by quinacrine. *Lancet* 1994; **344**: 689.

Leishmaniasis. Mepacrine has been suggested for intralésional injection in the treatment of early noninflamed nodular lesions of cutaneous leishmaniasis (p.824) due to *Leishmania tropica*, *L. major*, *L. mexicana*, *L. panamensis*, or *L. peruviana*.¹ The suggested course of treatment was 3 intralésional injections of a 5% solution of mepacrine given at intervals of 3 to 5 days. However, local infiltration of drugs can be difficult and painful.

1. WHO. Control of the leishmaniasis. *WHO Tech Rep Ser* 793 1990.

Sclerotherapy. Intrapleural instillations of mepacrine hydrochloride or mesilate have been used as sclerosants in the management of malignant pleural effusions (p.659) and recurrent pneu-

mothorax but the treatment is associated with pain and a high frequency of toxic effects.

Preparations

Proprietary Preparations (details are given in Part 3)

India: Maladin.

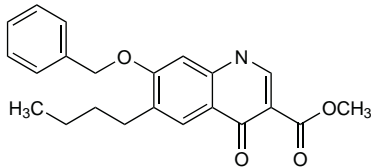
Methyl Benzoate (BAN)

Nequinat (USAN, pINN); AY-20385; ICI-55052; Néquinat; Nequinato; Nequinatum. Methyl 7-benzyloxy-6-butyl-1,4-dihydro-4-oxoquinoline-3-carboxylate.

Нехинат

$C_{22}H_{23}NO_4 = 365.4$.

CAS — 13997-19-8.



Profile

Methyl benzoate is an antiprotozoal used in veterinary practice with clodipol (p.831) for the prevention of coccidiosis in poultry.

Metronidazole (BAN, USAN, rINN)

Bayer-5360; Metronidazol; Metronidazole; Metronidazolum; NSC-50364; RP-8823; SC-10295. 2-(2-Methyl-5-nitroimidazol-1-yl)ethanol.

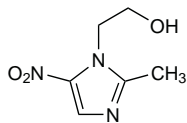
Метронидазол

$C_6H_9N_3O_3 = 171.2$.

CAS — 443-48-1.

ATC — A01AB17; D06BX01; G01AF01; J01XD01; P01AB01.

ATC Vet — QA01AB17; QD06BX01; QG01AF01; QJ01XD01; QP51AA01.



Pharmacopoeias. In *Chin.*, *Eur.* (see p.vii), *Int.*, *Jpn.*, *US*, and *Viet*.

Ph. Eur. 6.2 (Metronidazole). A white or yellowish, crystalline powder. Slightly soluble in water, in alcohol, in acetone, and in dichloromethane. Protect from light.

USP 31 (Metronidazole). White to pale yellow, odourless crystals or crystalline powder. It darkens on exposure to light. Sparingly soluble in water and in alcohol; slightly soluble in chloroform and in ether. Store at a temperature of 25°, excursions permitted between 15° and 30°. Protect from light.

Incompatibility. See below.

Metronidazole Benzoate (BAN, rINN)

Benzoato de metronidazol; Benzoyl Metronidazole; Metronidatsolbenzoatti; Metronidazolbenzoat; Metronidazol-benzoat; Métronidazole, benzoate de; Metronidazol benzoas; Metronidazol benzoatas; RP-9712. 2-(2-Methyl-5-nitroimidazol-1-yl)ethyl benzoate.

Метронидазола Бензоат

$C_{13}H_{13}N_3O_4 = 275.3$.

CAS — 13182-89-3.

ATC — A01AB17; D06BX01; G01AF01; J01XD01; P01AB01.

ATC Vet — QA01AB17; QD06BX01; QG01AF01; QJ01XD01; QP51AA01.

Pharmacopoeias. In *Eur.* (see p.vii), *Int.*, and *US*.

Ph. Eur. 6.2 (Metronidazole Benzoate). White or slightly yellowish, crystalline powder or flakes. Practically insoluble in water; slightly soluble in alcohol; soluble in acetone; freely soluble in dichloromethane. Protect from light.

USP 31 (Metronidazole Benzoate). A white to slightly yellow, crystalline powder. Practically insoluble in water; slightly soluble in alcohol; soluble in acetone; freely soluble in dichloromethane; very slightly soluble in solvent ether. Store at a temperature of 25°, excursions permitted between 15° and 30°. Protect from light.

The symbol † denotes a preparation no longer actively marketed

Metronidazole Hydrochloride (BANM, USAN, rINN)

Hidrocloruro de metronidazol; Métronidazole, Chlorhydrate de; Metronidazol Hydrochloridum; SC-32642.

Метронидазола Гидрохлорид

$C_6H_9N_3O_3 \cdot HCl = 207.6$.

CAS — 69198-10-3.

ATC — A01AB17; D06BX01; G01AF01; J01XD01; P01AB01.

ATC Vet — QA01AB17; QD06BX01; QG01AF01; QJ01XD01; QP51AA01.

Incompatibility. Solutions of metronidazole hydrochloride have a low pH, usually of less than 2.0, before dilution and neutralisation for intravenous use. These undiluted solutions react with aluminium in equipment such as needles to produce reddish-brown discoloration, and a precipitate has been reported with ready-to-use preparations of metronidazole hydrochloride, although this occurred after contact for 6 hours or more.^{1,2}

Several studies have assessed the compatibility of antibacterial injections and other drugs when added to metronidazole solution for intravenous infusion.³⁻⁷ Results have varied according to the criteria applied and the preparations and conditions used. Physical incompatibilities due to the low pH of metronidazole injections appear to be more of a problem than chemical incompatibility. Regardless of these studies, it is generally recommended that other drugs should not be added to intravenous solutions of metronidazole or its hydrochloride. Specific information on the compatibility of individual formulations may be found in the manufacturers' literature.

1. Schell KH, Copeland JR. Metronidazole hydrochloride-aluminum interaction. *Am J Hosp Pharm* 1985; **42**: 1040, 1042.

2. Struthers BJ, Parr RJ. Clarifying the metronidazole hydrochloride-aluminum interaction. *Am J Hosp Pharm* 1985; **42**: 2660.

3. Bisaillon S, Sarrazin R. Compatibility of several antibiotics or hydrocortisone when added to metronidazole solution for intravenous infusion. *J Parenter Sci Technol* 1983; **37**: 129-32.

4. Gupta VD, Stewart KR. Chemical stabilities of hydrocortisone sodium succinate and several antibiotics when mixed with metronidazole injection for intravenous infusion. *J Parenter Sci Technol* 1985; **39**: 145-8.

5. Gupta VD, et al. Chemical stabilities of cefamandole nafate and metronidazole when mixed together for intravenous infusion. *J Clin Hosp Pharm* 1985; **10**: 379-83.

6. Barnes AR. Chemical stabilities of cefuroxime sodium and metronidazole in an admixture for intravenous infusion. *J Clin Pharm Ther* 1990; **15**: 187-96.

7. Nabata MC, et al. Stability of metronidazole and ceftiozime sodium in ready-to-use metronidazole bags stored at 4 and 25° C. *Am J Health-Syst Pharm* 1996; **53**: 1046-8.

Adverse Effects

The adverse effects of metronidazole are generally dose-related. The most common are gastrointestinal disturbances, especially nausea and an unpleasant metallic taste. Vomiting, and diarrhoea or constipation may also occur. A furred tongue, glossitis, and stomatitis may be associated with an overgrowth of *Candida*. There have been rare reports of antibiotic-associated colitis associated with metronidazole, although it is also used in the treatment of this condition.

Weakness, dizziness, ataxia, headache, drowsiness, insomnia, and changes in mood or mental state such as depression or confusion have also been reported. Peripheral neuropathy, usually presenting as numbness or tingling in the extremities, and epileptiform seizures have been associated with high doses of metronidazole or prolonged treatment.

Temporary moderate leucopenia and thrombocytopenia may occur in some patients receiving metronidazole. Skin rashes, urticaria, and pruritus occur occasionally and erythema multiforme, angioedema, and anaphylaxis have been reported rarely. Other adverse effects include urethral discomfort and darkening of the urine. Raised liver enzyme values, cholestatic hepatitis, and jaundice have occasionally been reported. Thrombophlebitis may follow intravenous use of metronidazole.

Studies have shown metronidazole to be mutagenic in bacteria and carcinogenic in some animals.

Carcinogenicity and mutagenicity. Metronidazole is mutagenic in bacterial assays, and its hydroxy metabolite even more so, but studies of mammalian cells *in vitro* and *in vivo* have not consistently demonstrated a mutagenic effect. Similarly, there is no uniformity in the limited data concerning genotoxicity in humans,¹ and although metronidazole has been classified as a carcinogen in animals, the evidence of human carcinogenicity is ambiguous. There was no appreciable increase in the incidence of cancer in a retrospective study of 771 patients given metronidazole for vaginal trichomoniasis,² nor in another similar study of 2460 patients.³ The first study did show an excess of cases of

lung cancer, although all 4 were in women who were smokers. Subsequent follow-up⁴ to 1984, covering a period of 15 to 25 years, still showed an excess of lung cancer cases even after allowing for smoking status. However, this follow-up also continued to show no significant increase overall in cancer-related morbidity or mortality. Follow-up⁵ of the patients from the second study for 11 to 15 years to 1984 also showed no increase in the overall incidence of cancers nor did it confirm any increase in lung cancer.

Risks to the fetus are discussed under Pregnancy in Precautions, below.

1. Bendesky A, et al. Is metronidazole carcinogenic? *Mutat Res* 2002; **511**: 133-44.
2. Beard CM, et al. Lack of evidence for cancer due to use of metronidazole. *N Engl J Med* 1979; **301**: 519-22.
3. Friedman GD. Cancer after metronidazole. *N Engl J Med* 1980; **302**: 519.
4. Beard CM, et al. Cancer after exposure to metronidazole. *Mayo Clin Proc* 1988; **63**: 147-53.
5. Friedman GD, Selby JV. Metronidazole and cancer. *JAMA* 1989; **261**: 866.

Effects on the blood. Adverse haematological effects associated with metronidazole therapy include a report of bone marrow aplasia, with leucopenia and markedly reduced erythropoiesis and granulopoiesis,¹ aplastic anaemia,² and the haemolytic-uraemic syndrome.³

1. White CM, et al. Bone marrow aplasia associated with metronidazole. *BMJ* 1980; **280**: 647.
2. Raman R, et al. Metronidazole induced aplastic anaemia. *Clinician* 1982; **46**: 46-8.
3. Powell HR, et al. Haemolytic-uraemic syndrome after treatment with metronidazole. *Med J Aust* 1988; **149**: 222-3.

Effects on the ears. A review of reports of ototoxicity notified to the Australian Adverse Drug Reactions Advisory Committee revealed a number of cases of deafness associated with the use of metronidazole.¹

1. Anonymous. Drug-induced ototoxicity. *WHO Drug Inf* 1991; **5**: 12.

Effects on the eyes. Myopia which developed in a patient after 11 days of oral metronidazole for trichomoniasis had resolved 4 days after withdrawal of treatment, but recurred when she resumed treatment.¹

Optic neuropathies have also occurred.^{2,3} In one report, retrobulbar or optic neuritis was seen in 7 patients given oral metronidazole.² Dosage varied from 0.75 to 1 g daily and duration of treatment from 7 days to a year. Abnormalities included defects in colour vision, decreased vision, and scotomas. Vision improved on withdrawal of metronidazole, although there was a residual deficit in 2 patients.

1. Grinbaum A, et al. Transient myopia following metronidazole treatment for Trichomonas vaginalis. *JAMA* 1992; **267**: 511-12.
2. Putnam D, et al. Metronidazole and optic neuritis. *Am J Ophthalmol* 1991; **112**: 737.
3. McGrath NM, et al. Reversible optic neuropathy due to metronidazole. *Clin Experiment Ophthalmol* 2007; **35**: 585-6.

Effects on the gastrointestinal tract. ANTIBIOTIC-ASSOCIATED COLITIS. Reports of pseudomembranous colitis associated with the use of metronidazole.

1. Thomson G, et al. Pseudomembranous colitis after treatment with metronidazole. *BMJ* 1981; **282**: 864-5.
2. Daly JJ, Chowdary KVS. Pseudomembranous colitis secondary to metronidazole. *Dis Colon Rectum* 1983; **26**: 573-4.

Effects on the liver. Severely elevated liver enzyme values, consistent with a drug-induced hepatitis, occurred in a patient given metronidazole hydrochloride 500 mg every 6 hours intravenously for 4 days. He was also receiving cefepime sodium and tobramycin sulfate.¹ A case of reversible hepatotoxicity caused by an overdose of metronidazole 12.5 g has also been reported.²

1. Appleby DH, Vogtland HD. Suspected metronidazole toxicity. *Clin Pharm* 1983; **2**: 373-4.
2. Lam S, Bank S. Hepatotoxicity caused by metronidazole overdose. *Ann Intern Med* 1995; **122**: 803.

Effects on the nervous system. ASEPTIC MENINGITIS. A 42-year-old man had 3 episodes of aseptic meningitis during treatment with oral metronidazole as part of an eradication regimen for *Helicobacter pylori* infection.¹ On each occasion his symptoms resolved spontaneously when eradication treatment was stopped and recurred when treatment was restarted. The aseptic meningitis was attributed to the metronidazole and the patient later tolerated an eradication treatment regimen containing a proton-pump inhibitor and a macrolide.

1. Khan S, et al. Metronidazole-induced aseptic meningitis during *Helicobacter pylori* eradication therapy. *Ann Intern Med* 2007; **146**: 395-6.

CEREBELLAR TOXICITY. Ataxia and dysarthria have been reported in 2 patients taking oral metronidazole plus intravenous cefepime or oral levofloxacin.¹ Symptoms occurred about one month after starting treatment and resolved 2 to 5 weeks after stopping metronidazole.

1. Woodruff BK, et al. Reversible metronidazole-induced lesions of the cerebellar dentate nuclei. *N Engl J Med* 2002; **346**: 68-9.

CONVULSIONS. Reports of convulsions associated with metronidazole therapy (usually in high doses or in patients with renal impairment).

1. Halloran TJ. Convulsions associated with high cumulative doses of metronidazole. *Drug Intell Clin Pharm* 1982; **16**: 409.