

Antiepileptics. For increased *phenytoin* concentrations when given with levamisole and fluorouracil, see Interactions, Antineoplastic, under Phenytoin, p.499.

Pharmacokinetics

Levamisole is rapidly absorbed from the gastrointestinal tract. Maximum plasma concentrations are attained within 1.5 to 2 hours. It is extensively metabolised in the liver. The plasma half-life for levamisole is 3 to 4 hours and for the metabolites is 16 hours. It is excreted mainly in the urine as metabolites and a small proportion in the faeces. About 70% of a dose is excreted in the urine over 3 days, with about 5% as unchanged levamisole.

References.

1. Luyckx M, *et al.* Pharmacokinetics of levamisole in healthy subjects and cancer patients. *Eur J Drug Metab Pharmacokin* 1982; **7**: 247–54.
2. Kouassi E, *et al.* Novel assay and pharmacokinetics of levamisole and p-hydroxylevamisole in human plasma and urine. *Biopharm Drug Dispos* 1986; **7**: 71–89.

Uses and Administration

Levamisole hydrochloride is the active laevo-isomer of tetramisole hydrochloride. It is used as an anthelmintic and as an adjuvant in malignant disease. It has also been tried in several conditions where its stimulant effect on the depressed immune response might be useful.

Levamisole is active against intestinal nematode worms and appears to act by paralysing susceptible worms which are subsequently eliminated from the intestines. In particular, levamisole is effective in the treatment of ascariasis (p.134). It is also used in hookworm infections (p.136).

Doses of levamisole hydrochloride are expressed in terms of the equivalent amount of levamisole. Levamisole hydrochloride 1.18 g is equivalent to about 1 g of levamisole. The usual adult dose in ascariasis is 150 mg of levamisole orally as a single dose; children have been given 3 mg/kg as a single dose. For the hookworm infection ancyllostomiasis or for mixed ascariasis-hookworm infections, both adults and children may be given 2.5 mg/kg as a single dose, repeated after 7 days in cases of severe hookworm infection.

Levamisole influences host defences by modulating cell-mediated immune responses; it restores depressed T-cell functions and has been described as an immunostimulant, although stimulation above normal levels does not seem to occur. It has been tried in many disorders, including bacterial and viral infections and rheumatic disorders, although in these conditions results have not been encouraging.

Levamisole has also been used as an adjunct in patients with malignant disease, although it is not clear that any response is due to its action on the immune system. Adjuvant treatment with levamisole and fluorouracil has been given to reduce recurrence after resection of adenocarcinoma of the colon with regional lymph node involvement (but see Malignant Neoplasms, below).

References.

1. Amery WKP, Bruynseels JPJM. Levamisole, the story and the lessons. *Int J Immunopharmacol* 1992; **14**: 481–6.
2. Scheinfeld N, *et al.* Levamisole in dermatology: a review. *Am J Clin Dermatol* 2004; **5**: 97–104.

Malignant neoplasms. Levamisole has been tried in the adjuvant treatment of various malignant neoplasms^{1,2} with conflicting results. Based on the results of early adjuvant trials,^{3,5} levamisole was used as standard therapy to modulate fluorouracil in patients with colorectal cancer (p.665), particularly in the USA. However, whether levamisole actually added to the beneficial effect of adjuvant fluorouracil was unclear. Adjuvant levamisole alone was no more effective than placebo in 1 study,⁶ and more recent trials have indicated that levamisole is no more effective than placebo when added to fluorouracil,⁷ or to fluorouracil plus folinic acid.⁸

1. Spreafico F. Use of levamisole in cancer patients. *Drugs* 1980; **20**: 105–16.
2. Amery WK, Butterworth BS. Review/commentary: the dosage regimen of levamisole in cancer: is it related to efficacy and safety? *Int J Immunopharmacol* 1983; **5**: 1–9.

3. Laurie JA, *et al.* Surgical adjuvant therapy of large-bowel carcinoma: an evaluation of levamisole and the combination of levamisole and fluorouracil: the North Central Cancer Treatment Group and the Mayo Clinic. *J Clin Oncol* 1989; **7**: 1447–56.
4. Moertel CG, *et al.* Levamisole and fluorouracil for adjuvant therapy of resected colon carcinoma. *N Engl J Med* 1990; **322**: 352–8.
5. Moertel CG, *et al.* Fluorouracil plus levamisole as effective adjuvant therapy after resection of stage III colon carcinoma: a final report. *Ann Intern Med* 1995; **122**: 321–6.
6. Chlebowski RT, *et al.* Long-term survival following levamisole or placebo adjuvant treatment of colorectal cancer: a Western Cancer Study Group trial. *Oncology* 1988; **45**: 141–3.
7. QUASAR Collaborative Group. Comparison of fluorouracil with additional levamisole, higher-dose folinic acid, or both, as adjuvant chemotherapy for colorectal cancer: a randomised trial. *Lancet* 2000; **355**: 1588–96.
8. Wolmark N, *et al.* Clinical trial to assess the relative efficacy of fluorouracil and leucovorin, fluorouracil and levamisole, and fluorouracil, leucovorin, and levamisole in patients with Dukes' B and C carcinoma of the colon: results from National Surgical Adjuvant Breast and Bowel Project C-04. *J Clin Oncol* 1999; **17**: 3553–9.

Mansonella infections. Levamisole is one of the drugs that has been suggested for the treatment of *Mansonella* infections (p.137). There have been reports^{1,2} of response when given with mebendazole.

1. Maertens K, Wery M. Effect of mebendazole and levamisole on *Onchocerca volvulus* and *Dipetalonema perstans*. *Trans R Soc Trop Med Hyg* 1975; **69**: 359–60.
2. Bernberg HC, *et al.* The combined treatment with levamisole and mebendazole for a perstans-like filarial infection in Rhodesia. *Trans R Soc Trop Med Hyg* 1979; **73**: 233–4.

Mouth ulceration. Levamisole might be beneficial in severe mouth ulceration (p.1700) but is limited by its adverse effects. A review¹ of its use in recurrent aphthous stomatitis indicated that beneficial results have been reported with levamisole in open studies, but results of double-blind studies have been conflicting. Nevertheless, there have been patients with severe recurrent aphthous stomatitis refractory to all other modes of treatment who have responded to levamisole. Dosage has been with 150 mg daily in divided doses given for 3 days at the first sign of ulceration, followed by 11 days without treatment, repeated as necessary.

1. Miller MF. Use of levamisole in recurrent aphthous stomatitis. *Drugs* 1980; **20**: 131–6.

Renal disorders. In a randomised double-blind study, children with frequently relapsing corticosteroid-sensitive and corticosteroid-dependent nephrotic syndrome were given placebo or levamisole 2.5 mg/kg on alternate days and steroid therapy was gradually withdrawn.¹ Of 31 children being treated with levamisole, 14 were still in remission 112 days after the start of the study compared with 4 of 30 receiving placebo. There have been subsequent reports of adjunctive use in children with nephrotic syndrome,^{2,6} but its place in therapy remains to be established. For a discussion of the treatment of glomerular kidney disorders, including the nephrotic syndrome, see p.1504.

1. British Association for Paediatric Nephrology. Levamisole for corticosteroid-dependent nephrotic syndrome in childhood. *Lancet* 1991; **337**: 1555–7.
2. Donia AF, *et al.* Levamisole: adjunctive therapy in steroid dependent minimal change nephrotic children. *Pediatr Nephrol* 2002; **17**: 355–8.
3. Fu LS, *et al.* Levamisole in steroid-sensitive nephrotic syndrome children with frequent relapses and/or steroid dependency: comparison of daily and every-other-day usage. *Nephron Clin Pract* 2004; **97**: c137–c141.
4. Sümeği V, *et al.* Long-term effects of levamisole treatment in childhood nephrotic syndrome. *Pediatr Nephrol* 2004; **19**: 1354–60.
5. Al-Saran K, *et al.* Experience with levamisole in frequently relapsing, steroid-dependent nephrotic syndrome. *Pediatr Nephrol* 2006; **21**: 201–5.
6. Boyer O, *et al.* Short- and long-term efficacy of levamisole as adjunctive therapy in childhood nephrotic syndrome. *Pediatr Nephrol* 2008; **23**: 575–80.

Vitiligo. In a study¹ involving 36 patients with limited slow-spreading vitiligo, response to levamisole treatment occurred in 34 within 2 to 4 months. Patients received 150 mg of oral levamisole daily on 2 consecutive days each week. Patients who were additionally treated with topical fluocinolone or clobetasol had higher rates of repigmentation. A later controlled study² involving 43 patients reported less benefit.

The usual treatment of vitiligo is discussed under Pigmentation Disorders, p.1582.

1. Pasricha JS, Khara V. Effect of prolonged treatment with levamisole on vitiligo with limited and slow-spreading disease. *Int J Dermatol* 1994; **33**: 584–7.
2. Agarwal S, *et al.* A randomized placebo-controlled double-blind study of levamisole in the treatment of limited and slowly spreading vitiligo. *Br J Dermatol* 2005; **153**: 163–6.

Preparations

USP 31: Levamisole Hydrochloride Tablets.

Proprietary Preparations (details are given in Part 3)

Arg.: Levam; **Meglum. Austral.:** Ergamisolt; **Belg.:** Ergamisolt; **Braz.:** Ascandil; **Canada:** Ergamisolt; **Cz.:** Decaris†; **Ger.:** Ergamisolt; **Gr.:** Ergamisolt; **Hong Kong:** Decaris; **Hung.:** Decaris; **India:** Levomol; **Vermisil;** **Viz.:** **Indon.:** Askamex; **Ir.:** Ketrax†; **Israel:** Ergamisolt; **Mex.:** Decaris; **Neth.:** Ergamisolt; **Rus.:** Decaris (Декарис); **S.Afr.:** Ergamisolt; **Turk.:** Paraks; **Sitraks;** **UK:** Ketrax†; **USA:** Ergamisolt; **Venez.:** Decaris†.

Male Fern

Aspidium; Farnwurzel; Felce Maschio; Feto Macho; Filix Mas; Fougère Mâle; Helecho macho; Rhizoma Filicis Maris.

Шитовник Мужской

Pharmacopoeias. In *Chin.*

Profile

Male fern consists of the rhizome, frond-bases, and apical bud of *Dryopteris filix-mas* agg. (Polypodiaceae), collected late in the autumn, divested of the roots and dead portions and carefully dried, retaining the internal green colour. It contains not less than 1.5% of filicin. During storage the green colour of the interior gradually disappears, often after a lapse of 6 months, and such material is unfit for medicinal use.

Filicin is the mixture of ether-soluble substances obtained from male fern. Its activity is chiefly due to flavaspidic acid, a phloroglucinol derivative.

Male fern has anthelmintic properties and was formerly used as male fern extract (aspidium oleoresin) for the expulsion of tapeworms. However, male fern is highly toxic and has been superseded by other drugs.

Adverse effects include headache, nausea and vomiting, severe abdominal cramp, diarrhoea, dyspnoea, albuminuria, hyperbilirubinaemia, dizziness, tremors, convulsions, visual disturbances including blindness (possibly permanent), stimulation of uterine muscle, coma, respiratory failure, bradycardia, and cardiac failure. Fatalities have occurred.

Preparations

Proprietary Preparations (details are given in Part 3)

Multi-ingredient: **Austria:** Digestodoron; **Ger.:** Digestodoron; **S.Afr.:** Digestodoron.

Mebendazole (BAN, USAN, rINN)

Mebendatsoli; Mebendazol; Mebendazolas; Mébendazole; Mebendazolium; R-17635. Methyl 5-benzoyl-1H-benzimidazol-2-yl-carbamate.

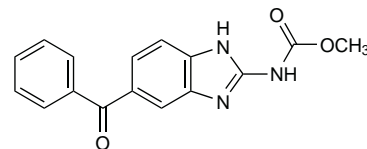
МЕБЕНДАЗОЛ

C₁₆H₁₃N₃O₃ = 295.3.

CAS — 31431-39-7.

ATC — P02CA01.

ATC Vet — QP52AC09.



Pharmacopoeias. In *Chin.*, *Eur.* (see p.vii), *Int.*, *US*, and *Viet. Ph. Eur.* **6.2** (Mebendazole). A white or almost white powder. It shows polymorphism. Practically insoluble in water, in alcohol, and in dichloromethane. Protect from light.

USP 31 (Mebendazole). A white to slightly yellow, almost odourless, powder. Practically insoluble in water, in alcohol, in chloroform, in ether, and in dilute mineral acids; freely soluble in formic acid.

Adverse Effects

Since mebendazole is poorly absorbed from the gastrointestinal tract at the usual therapeutic doses, adverse effects have generally been restricted to gastrointestinal disturbances, such as transient abdominal pain and diarrhoea, and have tended to occur in patients being treated for heavy intestinal infection. Headache and dizziness have been reported. Adverse effects have been reported more frequently with the high doses tried in echinococcosis and have included allergic reactions, raised liver enzyme values, alopecia, and bone marrow depression.

Incidence of adverse effects. In the first phase¹ of WHO-coordinated multicentre studies on the treatment of echinococcosis (hydatid disease) involving *Echinococcus granulosus* or *E. multilocularis*, the most frequent adverse effects in the 139 patients given high-dose mebendazole, generally for 3 months, were reduced leucocyte count (25 patients), gastrointestinal symptoms (22), and raised serum-transaminase values (22). Other adverse effects were allergic conditions such as fever and skin reactions (4), CNS symptoms including headache (6), and loss of hair (7). Seven patients stopped treatment because of adverse effects.

The second phase of studies² compared albendazole with mebendazole in more prolonged high-dose schedules for cystic *E. granulosus* infection. Adverse effects were similar to those reported with the first phase. However, in the first phase the allergic consequences of the 14 ruptured lung cysts and the 4 ruptured