

**Ichthammol** (BAN)

Ammonii Bituminosulfonas; Ammonii Sulfogryodalas; Ammonio Sulfoitoliato; Ammonium Bithiolium; Ammonium Bitumenosulfonicum; Ammonium Bituminosulphonate; Ammonium Ichthosulphonate; Ammonium Sulfobituminosum; Ammonium Sulpho-ichtholate; Amonowy sulfobituminian; Bithiolate Ammonique; Bithyl; Bitiol; Bithiolato amónico; Bitomol; Bituminol; Ichthammol; Ichthamolis; Ichthammolum; Ichthamol; Ichthosulphol; Ichthyl; Ichthylammonium; Ictamol; Ictiolsulfonato amónico; Ihtamol; Iktammol; Iktammol; Sulfobituminato amónico; Sulfoitoliato amónico.

Ихтаммол; Ихтиол

CAS — 8029-68-3.

**Pharmacopoeias.** In *Chin.*, *Eur.* (see p.vii), *Jpn.* and *US*.

**Ph. Eur. 6.2** (Ichthammol). A dense blackish-brown liquid. It is obtained by distillation of certain bituminous schists, sulfonation of the distillate, and neutralisation of the product with ammonia. It contains not less than 4.5% and not more than 7.0% of total ammonia, not less than 10.5% of organically combined sulfur, calculated with reference to the dried substance, and not more than 20% of the total sulfur in the form of sulfates.

Miscible with water and with glycerol; slightly soluble in alcohol, in fatty oils, and in liquid paraffin; forms homogeneous mixtures with wool fat and soft paraffin.

**USP 31** (Ichthammol). A reddish-brown to brownish-black viscous fluid with a strong characteristic empyreumatic odour. It is obtained by the destructive distillation of a bituminous schist, sulfonation of the distillate, and neutralisation of the product with ammonia. It yields not less than 10.0% of total sulfur and not less than 2.5% of ammonia. Miscible with water, with glycerol, and with fixed oils and fats. Partially soluble in alcohol and in ether.

**Incompatibility.** Ichthammol is incompatible with wool alcohols.

**Profile**

Ichthammol has slight bacteriostatic properties and is used in a wide range of topical preparations, for a variety of skin disorders; it has also been used in suppositories for anorectal disorders. Ichthammol is often used with zinc oxide in medicated bandages for chronic lichenified eczema (p.1579). Ichthammol may be slightly irritant to the skin and there have been rare reports of hypersensitivity.

Light Ammonium Bituminosulfonate (Ammoniumbituminosulfonat Hell) is produced from the light distillate fraction of shale oil.

Ammoniumsulfobitol, an ammonium bituminosulfonate similar to ichthammol but with a low sulfur content, was commercially available as Tumenol Ammonium.

**Preparations**

**BP 2008:** Zinc and Ichthammol Cream;

**USP 31:** Ichthammol Ointment.

**Proprietary Preparations** (details are given in Part 3)

**Austral:** Egoderm; **Austria:** Ichtho-Bad; Ichtholan; Ichtopur; **Belg:** Bithiol; Poudre Velours; **Cz:** Ichtoxy; **Fr:** Gelictar; **Ger:** Ichtho-Bad; Ichtholan; Ichtholan spezial; Ichthylol; Thiobitum; **Neth:** Daroderm Trekzalf; Trekzalf; **Switz:** Ichtho-Bad; Ichtholan; **Turk:** Ichtyol; Pomat Ichthyole; Pomade Ichthyole.

**Multi-ingredient:** **Arg:** Cicatrina; **Austral:** Egoderm; Ichthaband; **Austria:** Aknemycin compositum; Delta-Hadensa; Hadensa; Ichth-Oestren; Inotylol; **Belg:** Antipiol; Inotylol; **Canad:** Boil Ease; **Cz:** Pityol; Saloxyl; **Denm:** Inotylol; **Fin:** Hadensa; **Fr:** Anaxery; Gelictar Fort; Inotylol; Node DS; Novophane S; Oxythylol; Phytolol; Phytololther; Provictol; Selegel; Squaphane Masque-Creme; **Ger:** Aknemycin; **Hong Kong:** Acnederma; Egoderm; **Israe:** Aknemycin; Inotylol; **Ital:** Antiemoroidali; Dermatar; Ichthopaste; Inotylol; Tricoderm F; **Malaysia:** Acnederma; Egoderm; **Norw:** Inotylol; **NZ:** Acnederma; Egoderm; **Pol:** Neo-Tormentil; Tormentile Forte; Tormentil; **Port:** Efluvium Anti-caspa; Efluvium Anti-seborreico; Oleoban Composito; Pansebase Composito; Sepcel Composito; **Rus:** Bethiol (Бетхиол); **S.Afr:** Antipeol; **Singapore:** Egoderm; **Spain:** Hadensa; Ictamen; Lamnotyl; **Swed:** Inotylol; **Switz:** Aknemycin; Bain extra-doux dermatologique; Epithelial; Furodermal; Leucen; Radix Riccovant; **Turk:** Hadensa; **UK:** Antipeol; Ichthopaste; Ichthaband; St James Balm; **USA:** Boil Ease; Boil Salve; Medicone Derma; **Venez:** Node DS.

**Ictasol** (USAN)

Ictasol; Ichthyl-Natrium Hell; Light Sodium Bituminosulphonate; Natrium Sulfobituminosum Decoloratum; Sulfobituminato sódico; Sulfobituminato sódico decolorado.

$C_{28}H_{36}Na_2O_6S_3 = 610.8$ .

CAS — 12542-33-5; 1340-06-3.

ATC — D10BX01.

ATC Vet — QD10BX01.

**Profile**

Ictasol is a sodium bituminosulfonate produced from the light distillate fraction of shale oil. Sodium bituminosulfonate is obtained by the destructive distillation of certain bituminous schists, sulfonation of the distillate, and neutralisation of the product with sodium hydroxide.

Ictasol has similar properties to ichthammol (above) and is used in a wide range of preparations for a variety of skin disorders.

The symbol † denotes a preparation no longer actively marketed

**Preparations**

**Proprietary Preparations** (details are given in Part 3)

**Austria:** Crino Cordes; Ichthraletten; Lavichthol; **Ger:** Aknichthol Creme; Crino Cordes N; Dermichthol; Ichthoderm; Ichtholan T; Ichthosin; Ichthraletten; Leukichtan; Solutio Cordes.

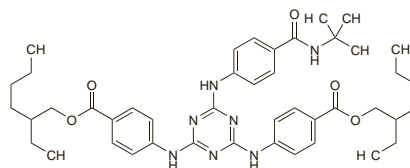
**Multi-ingredient:** **Arg:** Selegel; **Austria:** Aknichthol; Ichthalgan forte; Ichtho-Bello; Ichtho-Cortin; Leukichtan; **Chile:** Ichthosoft; **Fr:** I-Soft; Ichthosoft; Sebosquim; **Ger:** Aknederma Neu; Aknichthol N; Ichthalgan; Ichtho-Bello compositum S; Ichtho-Bello; Ichthocortin; Ichthosetral; Pelvichthol N; **Switz:** Aknichthol N.

**Isotrizinol** (USAN)

Diethylhexyl Butamido Triazone; Diethylhexylbutamido Triazone; Diocetylbutamidotriazone. Bis(2-ethylhexyl) 4,4'-[6-[(4-(tert-butylcarbamoyl)phenyl)amino]-1,3,5-triazine-2,4-diyl]diiminodibenzoate.

$C_{44}H_{59}N_7O_5 = 766.0$ .

CAS — 154702-15-5.



NOTE. Uvasorb HEB is a trade name that has been used for isotrizinol.

**Profile**

Isotrizinol is used as a sunscreen (p.1576). It is effective against UVB light (for definitions, see p.1580).

**Preparations**

**Proprietary Preparations** some preparations are listed in Part 3.

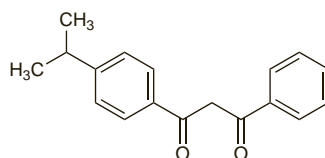
**Isopropylidibenzoylmethane**

Isopropylidibenzoylmetano. 1-[4-(1-Methylethyl)phenyl]-3-phenyl-1,3-propanedione.

Изопропилидбензоилметан

$C_{18}H_{18}O_2 = 266.3$ .

CAS — 63250-25-9.

**Profile**

Isopropylidibenzoylmethane, a substituted dibenzoylmethane, is a sunscreen (p.1576) with actions similar to those of avobenzone (p.1589). It is effective against UVA light (for definitions, see p.1580).

**Preparations**

**Proprietary Preparations** some preparations are listed in Part 3.

**Isotretinoin** (BAN, USAN, rINN)

Isotretinoiini; Isotretinoína; Isotretinoine; Isotretinoinum; Isotretinoine; Isotretinoinas; Isotretinoína; 13-*cis*-Retinoic Acid; Ro-4-3780. (13Z)-15-Apo-β-caroten-15-oic acid; (2Z,4E,6E,8E)-3,7-Dimethyl-9-(2,6,6-trimethylcyclohex-1-enyl)nona-2,4,6,8-tetraenoic acid.

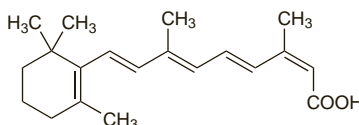
ИзоТРЕТИНОИН

$C_{20}H_{28}O_2 = 300.4$ .

CAS — 4759-48-2.

ATC — D10AD04; D10BA01.

ATC Vet — QD10AD04; QD10BA01.



**Pharmacopoeias.** In *Chin.*, *Eur.* (see p.vii), and *US*.

**Ph. Eur. 6.2** (Isotretinoin). A yellow or light orange, crystalline powder. Practically insoluble in water; slightly soluble in alcohol; soluble in dichloromethane. It is sensitive to air, heat, and

light, especially in solution. Store in airtight containers at a temperature not exceeding 25°. Protect from light. It is recommended that the contents of an opened container be used as soon as possible and that any unused part be protected by an atmosphere of an inert gas.

**USP 31** (Isotretinoin). Yellow crystals. Practically insoluble in water; sparingly soluble in alcohol, in isopropyl alcohol, and in macrogol 400; soluble in chloroform. Store in airtight containers under an atmosphere of an inert gas. Protect from light.

**Adverse Effects**

The adverse effects of isotretinoin and other oral retinoids are similar to those of vitamin A (see p.1971) and are generally reversible and dose-related. The most common are dryness of the mucous membranes and skin, which can often progress to cheilitis, epistaxis, conjunctivitis, localised exfoliation including palmo-plantar exfoliation, pruritus, erythematous rash, and skin fragility. Less common effects have included hair thinning (occasionally irreversible), hirsutism, photosensitivity, changes in skin pigmentation, paronychia, nail dystrophy, pyogenic granuloma, and increased sweating. Acne can be exacerbated at the beginning of isotretinoin treatment, and there are very rare reports of acne fulminans occurring. Less common adverse effects on the eyes include corneal opacities, visual disturbances such as blurred vision and colour vision disorders, impaired night vision that may persist, photophobia, and keratitis. Papilloedema, visual disturbances, headache, and nausea and vomiting can be signs and symptoms of benign intracranial hypertension. Arthralgia, myalgia, and back pain are commonly reported, and there have been rare reports of arthritis, osteoporosis, and tendinitis. Hyperostosis and calcinosis have also occurred, particularly in patients treated with high doses of isotretinoin over long periods for keratinisation disorders. Premature closure of the epiphyses has occurred in children treated with isotretinoin. Elevation of serum triglycerides is common, and pancreatitis has occurred in patients with high concentrations; cholesterol concentrations may also be increased. Increases in hepatic enzymes, erythrocyte sedimentation rate, and blood glucose can also occur. Alterations in haematological measures are common; there have also been reports of anaemia, thrombocytopenia, and neutropenia, and very rare reports of agranulocytosis. Other effects that have been reported rarely include gastrointestinal symptoms, hepatitis, hearing impairment, drowsiness, seizures, vasculitis, and hypersensitivity reactions including anaphylaxis. Mood changes, psychotic symptoms, depression, and suicidal behaviour have occurred in patients treated with oral isotretinoin. There may also be an association with skin infections and an inflammatory bowel syndrome.

Isotretinoin and other retinoids are teratogenic.

When isotretinoin is applied topically the adverse effects are similar to those of tretinoin (see p.1618).

◇ General references.

- Mills CM, Marks R. Adverse reactions to oral retinoids: an update. *Drug Safety* 1993; **9**: 280-90.
- Keefe M. Adverse reactions profile: retinoids. *Prescribers' J* 1995; **35**: 71-6.
- McLane J. Analysis of common side effects of isotretinoin. *J Am Acad Dermatol* 2001; **45**: S188-S194.
- British Association of Dermatologists. Advice on the safe introduction and continued use of isotretinoin in acne (2003). Available at: <http://www.bad.org.uk/healthcare/guidelines/acne.asp> (accessed 27/09/07).
- Charakida A, et al. Safety and side effects of the acne drug, oral isotretinoin. *Expert Opin Drug Saf* 2004; **3**: 119-29.
- Goldsmith LA, et al. American Academy of Dermatology consensus conference on the safe and optimal use of isotretinoin: summary and recommendations. *J Am Acad Dermatol* 2004; **50**: 900-906. Correction. *ibid.*; **51**: 348. [dose]

**Effects on the blood.** Serious adverse effects on the blood have been reported rarely with oral retinoids, and are thought to be idiosyncratic in nature. There have been reports of thrombocytopenia in patients taking isotretinoin<sup>1</sup> and etretinate.<sup>2,3</sup> A few cases of agranulocytosis have involved isotretinoin<sup>4</sup> and acitretin.<sup>5</sup> In contrast, there are also reports of transient and asymptomatic thrombocytosis associated with isotretinoin<sup>6</sup> and tretinoin.<sup>7,8</sup> Leucocytosis is often associated with the retinoic acid syndrome caused by tretinoin (p.1618).

- Moeller KE, Touma SC. Prolonged thrombocytopenia associated with isotretinoin. *Ann Pharmacother* 2003; **37**: 1622-4.
- Naldi L, et al. Etretinate therapy and thrombocytopenia. *Br J Dermatol* 1991; **124**: 395.

- Seishima M, *et al.* Thrombocytopenia possibly induced by etretinate in a psoriatic patient. *J Dermatol* 2005; **32**: 917–20.
- Waisman M. Agranulocytosis from isotretinoin. *J Am Acad Dermatol* 1988; **18**: 395–6.
- Chave TA, *et al.* Agranulocytosis and total scalp alopecia following acitretin. *Br J Dermatol* 2003; **148**: 1063–4.
- Jansen T, Altmeyer P. Thrombocytosis induced by low-dose isotretinoin. *Int J Dermatol* 2000; **39**: 956–7.
- Losada R, *et al.* Thrombocytosis in patients with acute promyelocytic leukaemia during all-trans retinoic acid treatment. *Br J Haematol* 1996; **95**: 704–5.
- Kentos A, *et al.* All-trans retinoic acid induced thrombocytosis in a patient with acute promyelocytic leukaemia. *Br J Haematol* 1997; **97**: 685.

**Effects on the cardiovascular system.** From 1983 to the end of 2005, Health Canada had received 29 reports of adverse cardiovascular effects in patients treated with isotretinoin, including myocardial infarction, stroke, and pulmonary embolism.<sup>1</sup> Thrombotic stroke has also been attributed to the use of acitretin in a woman treated for psoriasis,<sup>2</sup> and rare cases of myocardial ischaemia and infarction have been reported with etretinate.<sup>3</sup> Thromboembolic disorders have also occurred in patients given tretinoin for remission induction in acute promyelocytic leukaemia (see p.1618).

There are rare reports of isotretinoin causing cardiac arrhythmias, such as sinus tachycardia with right branch bundle block<sup>4</sup> and atrial tachycardia.<sup>5</sup>

- Springuel P, Roy G. Health Canada. Isotretinoin (Accutane): myocardial infarction, cerebrovascular and thromboembolic disorders. *Can Adverse React News* 2006; **16**: 3. Available at: [http://www.hc-sc.gc.ca/dhp-mps/medeff/bulletin/carn-bcei\\_v16n2-eng.php](http://www.hc-sc.gc.ca/dhp-mps/medeff/bulletin/carn-bcei_v16n2-eng.php) (accessed 28/07/08).
- Royer B, *et al.* Acitretin-associated thrombotic stroke. *Ann Pharmacother* 2002; **36**: 1879–82.
- Anonymous. Reports from regulatory agencies: etretinate. *WHO Drug Inf* 1987; **1**: 29.
- Charalabopoulos K, *et al.* Two new adverse effects of isotretinoin. *Br J Dermatol* 2003; **148**: 593.
- Hasdemir C, *et al.* Isotretinoin (13-cis-retinoic acid) associated atrial tachycardia. *Pacing Clin Electrophysiol* 2005; **28**: 348–9.

**Effects on the eyes.** A number of ocular adverse effects have been reported with oral isotretinoin, and these have been reviewed.<sup>1,2</sup> Using the WHO Causality Assessment Guide of Suspected Adverse Reactions, an analysis<sup>3</sup> of 2449 spontaneous reports found that decreased dark adaptation, ocular sicca, and the ocular signs and symptoms of intracranial hypertension, accounted for most of the reports that were certainly associated with isotretinoin. In some cases of intracranial hypertension the patient had also been taking other drugs, such as tetracyclines, that have also been associated with this effect. There was also a certain association between isotretinoin and abnormal meibomian gland secretion and gland atrophy, blepharokeratoconjunctivitis, corneal opacities, decreased vision, increased tear osmolality, keratitis, myopia, ocular discomfort and decreased tolerance to contact lenses, and photophobia. There was a probable association with reversible decreased colour vision and permanent loss of dark adaptation. Other effects that had been reported, but only possibly associated with isotretinoin, included corneal ulcers, diplopia, eyelid oedema, optic neuritis, permanent sicca, and subconjunctival haemorrhage.

There are fewer reports of ocular adverse effects with other oral retinoids. Intracranial hypertension with papilloedema, blurred vision, and headache, has been reported with acitretin, etretinate, and tretinoin.<sup>4–6</sup> A 1-year follow-up failed to find any evidence of ocular toxicity attributable to etretinate in 4 patients who had received long-term treatment, including 1 patient who had toxic optic neuropathy due to methotrexate and who was able to continue treatment with etretinate.<sup>7</sup> Ectropion has been associated with etretinate therapy in a patient.<sup>8</sup> Maculopathy occurred in a patient after a year of treatment with acitretin for psoriasis.<sup>9</sup>

- Fraunfelder FT, *et al.* Adverse ocular reactions possibly associated with isotretinoin. *Am J Ophthalmol* 1985; **100**: 534–7.
- Fraunfelder FT, *et al.* Ocular side effects possibly associated with isotretinoin usage. *Am J Ophthalmol* 2001; **132**: 299–305.
- Fraunfelder FW. Ocular side effects associated with isotretinoin. *Drugs Today* 2004; **40**: 23–7.
- Colucciello M. Pseudotumor cerebri induced by all-trans retinoic acid treatment of acute promyelocytic leukemia. *Arch Ophthalmol* 2003; **121**: 1064–5.
- Guirgis MF, Lueder GT. Intracranial hypertension secondary to all-trans retinoic acid treatment for leukemia: diagnosis and management. *J AAPOS* 2003; **7**: 432–4.
- Fraunfelder FW, Fraunfelder FT. Evidence for a probable causal relationship between tretinoin, acitretin, and etretinate and intracranial hypertension. *J Neuroophthalmol* 2004; **24**: 214–16.
- Pitts JF, *et al.* Etretinate and visual function: a 1-year follow-up study. *Br J Dermatol* 1991; **125**: 53–5.
- Brenner S, *et al.* Ectropion: an adverse effect of etretinate therapy for psoriasis. *DICP Ann Pharmacother* 1990; **24**: 1007.
- Lois N, White M. Acitretin-associated maculopathy. *Arch Ophthalmol* 2004; **122**: 928–30.

**Effects on the gastrointestinal tract.** A causal association has been suggested in cases of inflammatory bowel disease developing in patients taking oral isotretinoin.<sup>1,2</sup> Between 1997 and 2002 the FDA received 85 reports of Crohn's disease, ulcerative colitis, colitis, or haemorrhagic colitis attributed to isotretinoin;<sup>3</sup> the association was judged probable in 62 cases and possible in 23. Specific treatment, in addition to drug withdrawal, was required in 35 patients, 11 were hospitalised, and 7 underwent surgery. Rechallenge was positive in the 3 reported cases. The mechanism of this adverse effect is unknown, and because

young adulthood is the most common age for both the onset of inflammatory bowel disease and the use of isotretinoin, a coincidence could not be ruled out. The authors of this review suggested that isotretinoin should be used with caution in patients with a history of inflammatory bowel disease or symptoms suggestive of the condition and those who might be at increased risk because of a family history. Although there have been patients with inflammatory bowel disease who have received isotretinoin without adverse effect, there are some cases in which the condition was apparently exacerbated by isotretinoin.<sup>1,4</sup>

- Reniers DE, Howard JM. Isotretinoin-induced inflammatory bowel disease in an adolescent. *Ann Pharmacother* 2001; **35**: 1214–16.
- Passier JLM, *et al.* Isotretinoin-induced inflammatory bowel disease. *Neth J Med* 2006; **64**: 52–4.
- Reddy D, *et al.* Possible association between isotretinoin and inflammatory bowel disease. *Am J Gastroenterol* 2006; **101**: 1569–73.
- Godfrey KM, James MP. Treatment of severe acute with isotretinoin in patients with inflammatory bowel disease. *Br J Dermatol* 1990; **123**: 653–5.

**Effects on the liver.** Transient slight elevations of serum concentrations of liver enzymes are common with etretinate, but there have been few reports of acute hepatitis<sup>1,2</sup> or cholestatic jaundice.<sup>3</sup> Acute hepatitis may progress to chronic active hepatitis, despite stopping etretinate therapy<sup>4</sup> but studies of serial liver biopsies from patients receiving long-term etretinate have failed to show any significant chronic liver damage.<sup>5–7</sup> Licensed product information has included reports of hepatic fibrosis, necrosis, and/or cirrhosis.

An overview considered that some form of hepatotoxicity may be seen in up to 20% of patients treated with etretinate and significant liver disease in 1%.<sup>8</sup>

Isotretinoin may also cause mild elevations of liver enzymes and licensed product information states that hepatitis has occurred rarely. There is also a report of fatty liver.<sup>9</sup>

- Foged EK, Jacobsen FK. Side effects due to RO 10-9359 (Tigason). *Dermatologica* 1982; **164**: 395–403.
- Weiss VC, *et al.* Hepatotoxic reactions in a patient treated with etretinate. *Arch Dermatol* 1984; **120**: 104–6.
- Gavish D, *et al.* Cholestatic jaundice, an unusual side effect of etretinate. *J Am Acad Dermatol* 1985; **13**: 669–70.
- Weiss VC, *et al.* Chronic active hepatitis associated with etretinate therapy. *Br J Dermatol* 1985; **112**: 591–7.
- Glazer SD, *et al.* Ultrastructural survey and tissue analysis of human livers after a 6-month course of etretinate. *J Am Acad Dermatol* 1984; **10**: 632–8.
- Foged E, *et al.* Histologic changes in the liver during etretinate treatment. *J Am Acad Dermatol* 1984; **11**: 580–3.
- Roenigk HH, *et al.* Serial liver biopsies in psoriatic patients receiving long-term etretinate. *Br J Dermatol* 1985; **112**: 77–81.
- Boyd AS. An overview of the retinoids. *Am J Med* 1989; **86**: 568–74.
- Taylor AEM, Mitchison H. Fatty liver following isotretinoin therapy. *Br J Dermatol* 1991; **124**: 505–6.

**Effects on mental function.** Case reports provide evidence of depression, psychotic symptoms, suicide, and suicide attempts occurring as idiosyncratic adverse effects of isotretinoin. However, the high background prevalence of psychiatric illness among adolescents in general, and among patients with acne, are potentially confounding factors. Retrospective studies have not shown a clear cause and effect mechanism and prospective studies have been limited by sample size. Systematic reviews have found no strong evidence for an association between isotretinoin use and depression or suicidal behaviour, but noted that the evidence was not sufficiently compelling to rule out a weak association,<sup>1,2</sup> although other factors were probably more important.<sup>1</sup> In the absence of better evidence, monitoring for depression and other psychiatric effects has been advised for all patients receiving isotretinoin.<sup>3,5</sup>

Two cases of sustained dreaming have also been reported. After 2 to 3 weeks of oral isotretinoin, both patients reported changes in their dreaming pattern with a feeling that they had been 'dreaming all night'. The dreams persisted for 4 to 5 weeks after which they subsided despite continued isotretinoin therapy.<sup>6</sup>

- Marqueling AL, Zane LT. Depression and suicidal behavior in acne patients treated with isotretinoin: a systematic review. *Semin Cutan Med Surg* 2005; **24**: 92–102.
- Strahan JE, Raimor S. Isotretinoin and the controversy of psychiatric adverse effects. *Int J Dermatol* 2006; **45**: 789–99.
- Ng CH, Schweitzer I. The association between depression and isotretinoin use in acne. *Aust N Z J Psychiatry* 2003; **37**: 78–84.
- Adverse Drug Reactions Advisory Committee (ADRAC). Acne, isotretinoin and suicidality. *Aust Adverse Drug React Bull* 2005; **24**: 10. Also available at: <http://www.tga.health.gov.au/adr/aadr/aadr0506.htm> (accessed 27/09/07).
- Commission on Human Medicines/Medicines and Healthcare products Regulatory Agency. Isotretinoin (Roaccutane): psychiatric adverse reactions. *Current Problems* 2006; **31**: 8–9. Also available at: [http://www.mhra.gov.uk/home/idxplg?lscService=GET\\_FILE&dDocName=CON2025860&Revision=1&DocService=GET\\_LatestReleased](http://www.mhra.gov.uk/home/idxplg?lscService=GET_FILE&dDocName=CON2025860&Revision=1&DocService=GET_LatestReleased) (accessed 27/09/07).
- Gupta MA, Gupta AK. Isotretinoin use and reports of sustained dreaming. *Br J Dermatol* 2001; **144**: 919–20.

**Effects on the musculoskeletal system.** Hyperostotic changes (bone spurs) or calcification of tendons and ligaments, resembling *diffuse idiopathic skeletal hyperostosis* (DISH), have been reported with systemic retinoid therapy.<sup>1,2</sup> DISH-like hyperostotic changes are common in the general population and are associated with ageing; the use of chronic retinoid therapy may increase the risk of developing these changes. Reports have

particularly involved patients with keratinisation disorders being treated with large doses of retinoids for prolonged periods, and radiographic changes can be found in most patients after long-term treatment. However, minimal bone changes have also been found in radiographic studies of patients treated with isotretinoin in the dose range usually used to treat acne. Changes were also reported in a study of very low doses of isotretinoin used over 3 years to investigate skin cancer prevention. There have been few reports on the skeletal adverse effects of chronic low-dose etretinate and acitretin and results so far have been equivocal;<sup>2</sup> further studies are needed to clarify any effects. *Premature closure of the epiphyses* in children treated with retinoids has also been described.<sup>1</sup> Again, high doses or prolonged therapy were often used. There is limited evidence to suggest that children might also be at increased risk of slender long bones. There have been rare reports of changes in bone mineral density and *osteoporosis* from retinoid therapy, but there is limited evidence to confirm this association.<sup>1</sup> Ongoing clinical surveillance and periodic radiographic skeletal surveys have been recommended during long-term therapy; symptomatic bone spurs may be treated surgically.<sup>1</sup>

There have also been individual reports of *hypercalciuria*<sup>3</sup> or *hypercalcaemia*<sup>4–6</sup> associated with oral retinoid therapy.

**Muscular disorders** such as myalgia are not uncommon in patients treated with oral isotretinoin. Reversible myopathy with muscle pain, weakness, and raised creatine kinase concentrations has been described in a few patients treated with isotretinoin,<sup>7</sup> etretinate,<sup>8</sup> and acitretin.<sup>9</sup> Asymptomatic muscle damage has also been found in a study of patients given etretinate for at least a year.<sup>10</sup> Rhabdomyolysis and myoglobinuria have been described in a patient given isotretinoin for acne.<sup>11</sup> Myositis, often affecting the lower limbs, has occurred in a few patients given tretinoin for remission induction in acute promyelocytic leukaemia.<sup>12–15</sup> In one case, cardiac myositis also occurred.<sup>14</sup> Symptoms usually had an onset of 2 to 4 weeks and responded to stopping tretinoin and being treated with a corticosteroid. In a few cases, subsequent courses of tretinoin were given without recurrence of symptoms.<sup>14,15</sup> A review<sup>15</sup> suggested that some cases of myositis might have been associated with the retinoic acid syndrome (see under Tretinoin, p.1618) or Sweet's syndrome (see Effects on the Skin, under Tretinoin, p.1618).

- DiGiovanna JJ. Isotretinoin effects on bone. *J Am Acad Dermatol* 2001; **45**: S176–S182.
- Halverstad CP, *et al.* Lack of significant skeletal changes after long-term, low-dose retinoid therapy: case report and review of the literature. *J Cutan Med Surg* 2006; **10**: 291–9.
- Wilson DJ, *et al.* Skeletal hyperostosis and extraosseous calcification in patients receiving long-term etretinate (Tigason). *Br J Dermatol* 1988; **119**: 597–607.
- Valentic JP, *et al.* Hypercalcaemia associated with oral isotretinoin in the treatment of severe acne. *JAMA* 1983; **250**: 1899–1900.
- Horber FF, *et al.* Impaired renal function and hypercalcaemia associated with etretinate. *Lancet* 1984; **ii**: 1093.
- Akiyama H, *et al.* Hypercalcaemia due to all-trans retinoic acid. *Lancet* 1992; **339**: 308–9.
- Hodak E, *et al.* Muscle damage induced by isotretinoin. *BMJ* 1986; **293**: 425–6.
- Hodak E, *et al.* Etretinate-induced skeletal muscle damage. *Br J Dermatol* 1987; **116**: 623–6.
- Lister RK, *et al.* Acitretin-induced myopathy. *Br J Dermatol* 1996; **134**: 989–90.
- David M, *et al.* Electromyographic abnormalities in patients undergoing long-term therapy with etretinate. *J Am Acad Dermatol* 1988; **19**: 273–5.
- Guttman-Yassky E, *et al.* Acute rhabdomyolysis and myoglobinuria associated with isotretinoin treatment. *Int J Dermatol* 2003; **42**: 499–500.
- Miranda N, *et al.* Myositis with tretinoin. *Lancet* 1994; **334**: 1096.
- Martinez-Chamorro C, *et al.* ATRA-induced myositis in induction therapy of acute promyelocytic leukemia. *Haematologica* 2002; **87**: ECR08.
- Fabbiano F, *et al.* All-trans retinoic acid induced cardiac and skeletal myositis in induction therapy of acute promyelocytic leukaemia. *Br J Haematol* 2005; **129**: 444–5.
- Chan KH, *et al.* A case of all-trans retinoic acid-induced myositis in the treatment of acute promyelocytic leukaemia. *Clin Lab Haematol* 2005; **27**: 399–401.

**Effects on the nervous system.** There has been a report<sup>1</sup> of Guillain-Barré syndrome in 2 patients taking oral isotretinoin; both patients required ventilatory support and recovered slowly after treatment with intravenous immunoglobulins. There had been 1 case reported previously to the UK CSM. Intracranial hypertension, causing headaches and papilloedema, can occur with retinoids, including isotretinoin (see Effects on the Eyes, above).

- Pritchard J, *et al.* Guillain-Barré syndrome seen in users of isotretinoin. *BMJ* 2004; **328**: 1537.

**Effects on the respiratory system.** There have been reports of exercise-induced wheezing,<sup>1</sup> eosinophilic pleural effusion,<sup>2</sup> and worsening asthma<sup>3,4</sup> associated with isotretinoin therapy. The US manufacturers have records of adverse effects on the lung including worsening asthma, recurrent pneumothorax, interstitial fibrosis, and pulmonary granuloma.<sup>5</sup> A study of healthy subjects confirmed that lung function tests could deteriorate after treatment with isotretinoin.<sup>5</sup>

- Fisher DA. Exercise-induced bronchoconstriction related to isotretinoin therapy. *J Am Acad Dermatol* 1985; **13**: 524.
- Bunker CB, *et al.* Isotretinoin and eosinophilic pleural effusion. *Lancet* 1989; **i**: 435–6.



3. Sabroe RA, *et al.* Bronchospasm induced by isotretinoin. *BMJ* 1996; **312**: 886.
4. Kapur N, *et al.* Exacerbation of asthma by isotretinoin. *Br J Dermatol* 2000; **142**: 388–9.
5. Bunker CB, *et al.* Isotretinoin and the lung. *Br J Dermatol* 1991; **125** (suppl 38): 29.

**Effects on serum lipids.** The oral retinoids induce dose-dependent changes in serum lipids. There can be increases in very-low-density-lipoprotein cholesterol with smaller increases in low-density-lipoprotein cholesterol and reductions in high-density-lipoprotein cholesterol.<sup>1,2</sup> These effects appear to be unrelated to age or sex. They occur early during treatment and are usually reversible within a few weeks of withdrawal. Overall, the effect of isotretinoin is much greater than that of etretinate. Although the total cholesterol and triglyceride concentrations may remain within normal limits, types IIb and IV hyperlipidaemias are not uncommon among patients receiving oral retinoids. A large retrospective study<sup>3</sup> of patients treated with isotretinoin for acne found that of those who had normal concentrations before treatment, there was an increase in triglycerides in 44% and in total cholesterol in 31% of patients. Pancreatitis may be associated with hypertriglyceridaemia in patients treated with isotretinoin.<sup>4,7</sup>

Retinoids should be used with caution in patients with pre-existing hypertriglyceridaemia or in those at risk of developing hypertriglyceridaemia.<sup>1</sup> Use of fish oil containing eicosapentaenoic acid has been reported to attenuate retinoid-induced increases in serum-cholesterol and serum-triglyceride concentrations.<sup>2,8</sup>

1. Henkin Y, *et al.* Secondary dyslipidemia: inadvertent effects of drugs in clinical practice. *JAMA* 1992; **267**: 961–8.
2. Mantel-Teeuwisse AK, *et al.* Drug-induced lipid changes: a review of the unintended effects of some commonly used drugs on serum lipid levels. *Drug Safety* 2001; **24**: 443–56.
3. Zane LT, *et al.* A population-based analysis of laboratory abnormalities during isotretinoin therapy for acne vulgaris. *Arch Dermatol* 2006; **142**: 1016–22.
4. Flynn WJ, *et al.* Pancreatitis associated with isotretinoin-induced hypertriglyceridemia. *Ann Intern Med* 1987; **107**: 63.
5. McCarter TL, Chen YK. Marked hyperlipidemia and pancreatitis associated with isotretinoin therapy. *Am J Gastroenterol* 1992; **87**: 1855–8.
6. Jamshidi M, *et al.* Acute pancreatitis secondary to isotretinoin-induced hyperlipidemia. *J Okla State Med Assoc* 2002; **95**: 79–80.
7. Greene JP. An adolescent with abdominal pain taking isotretinoin for severe acne. *South Med J* 2006; **99**: 992–4.
8. Marsden JR. Effect of dietary fish oil on hyperlipidaemia due to isotretinoin and etretinate. *Hum Toxicol* 1987; **6**: 219–22.

**Effects on sexual function.** Ejaculatory failure has been reported in 3 men to be associated with isotretinoin treatment.<sup>1</sup> A possible mechanism could be an effect on the goblet cells of the seminal vesicles, an effect similar to the general reduction in body secretions which leads to dry mucous membranes.

1. Coleman R, MacDonald D. Effects of isotretinoin on male reproductive system. *Lancet* 1994; **344**: 198.

**Effects on the skin, hair, and nails.** Apart from the more common effects of oral retinoids on the skin and hair (see Adverse Effects, above), there have been isolated reports of various other reactions. Stickiness of the skin, particularly of the palms and soles, has been described with etretinate.<sup>1,2</sup> It has also occurred in a patient using topical tretinoin,<sup>3</sup> but not when he had previously taken a course of oral isotretinoin. Papules and pustules on the palms and soles have also been described with etretinate use.<sup>4</sup> In a series of 5 patients being treated for psoriasis, the lesions appeared 5 to 9 days after starting therapy and cleared spontaneously within a few weeks leaving a desquamation, despite continuing etretinate.

Granulomatous nodules or pyogenic granulomas have been reported with isotretinoin,<sup>5,6</sup> etretinate,<sup>7,8</sup> topical tretinoin,<sup>9,10</sup> and topical tazarotene.<sup>11</sup> Pyoderma gangrenosum has occurred in patients treated with isotretinoin.<sup>12–14</sup> Prurigo-like eruptions have been reported with etretinate.<sup>15</sup> Precipitation or exacerbation of erythroderma has been reported with isotretinoin,<sup>16</sup> etretinate,<sup>17</sup> and acitretin.<sup>18</sup>

Reversible chloasma (melasma) has been reported with isotretinoin.<sup>19</sup>

Acne fulminans is an uncommon complication of acne, developing as a sudden onset of ulcerative crusting acne with fever, weight loss, and musculoskeletal pain. Although isotretinoin may be used to treat this condition,<sup>20</sup> there have been reports of acne fulminans being precipitated by isotretinoin.<sup>21,22</sup> In some cases erythema nodosum has also developed,<sup>23,24</sup> but it has been suggested that this might be a manifestation of acne fulminans rather than an adverse effect of isotretinoin.<sup>24</sup> Erythema nodosum has also occurred in patients given oral tretinoin for remission induction in acute promyelocytic leukaemia. In a series of 4 cases, patients were successfully managed with a 5-day course of oral corticosteroid allowing the tretinoin course to be completed.<sup>25</sup> There has been a report of fatal toxic epidermal necrolysis associated with etretinate.<sup>26</sup>

For other reports of eruptions associated with vasculitic syndromes, see below. Painful scrotal ulcers and Sweet's syndrome (acute febrile neutrophilic dermatosis) are other reactions that have been reported with oral tretinoin (see p.1618). Skin erosion

after wax depilation has been reported in patients receiving retinoids (see Skin Fragility under Precautions, below).

Curling hair has been described in transplant recipients taking isotretinoin and azathioprine.<sup>27</sup> Oral retinoids have been associated with nail fragility, onycholysis,<sup>28</sup> paronychia, and other forms of nail dystrophy.<sup>29,30</sup>

1. Penneys NS, Hernandez D. A sticky problem with etretinate. *N Engl J Med* 1991; **325**: 521.
2. Higgins EM, Pembroke AC. Sticky palms—an unusual side-effect of etretinate therapy. *Clin Exp Dermatol* 1993; **18**: 389–90.
3. Lockridge J, *et al.* Tretinoin-induced sticky skin: a case report and review of the literature. *Cutis* 1999; **63**: 142–4.
4. David M, *et al.* Palmoplantar eruption associated with etretinate therapy. *Acta Derm Venereol (Stockh)* 1986; **66**: 87–9.
5. Lane PR, Hogan DJ. Granulomatous lesions appearing during isotretinoin therapy. *Can Med Assoc J* 1984; **130**: 550.
6. Türel A, *et al.* A rare side-effect of systemic isotretinoin treatment: pyogenic granuloma. *J Eur Acad Dermatol Venereol* 2003; **17**: 609–11.
7. Williamson DM, Greenwood R. Multiple pyogenic granulomata occurring during etretinate therapy. *Br J Dermatol* 1983; **109**: 615–17.
8. Kanoh H, *et al.* Granulomatous nodule on vocal cord possibly induced by etretinate therapy. *Br J Dermatol* 2000; **142**: 1258–60.
9. MacKenzie-Wood AR, Wood G. Pyogenic granuloma-like lesions in a patient using topical tretinoin. *Australas J Dermatol* 1998; **39**: 248–50.
10. Teknetzis A, *et al.* Pyogenic granulomas following topical application of tretinoin. *J Eur Acad Dermatol Venereol* 2004; **18**: 337–9.
11. Dawkins MA, *et al.* Pyogenic granuloma-like lesion associated with topical tazarotene therapy. *J Am Acad Dermatol* 2000; **43**: 154–5.
12. Hughes BR, Cunliffe WJ. Development of folliculitis and pyoderma gangrenosum in association with abdominal pain in a patient following treatment with isotretinoin. *Br J Dermatol* 1990; **122**: 683–7.
13. Gangaram HB, *et al.* Pyoderma gangrenosum following treatment with isotretinoin. *Br J Dermatol* 1997; **136**: 636–7.
14. Freiman A, Brassard A. Pyoderma gangrenosum associated with isotretinoin therapy. *J Am Acad Dermatol* 2006; **55** (suppl): S107–S108.
15. Boer J, Smeenk G. Nodular prurigo-like eruptions induced by etretinate. *Br J Dermatol* 1987; **116**: 271–4.
16. Wantzin GL, Thomsen K. A new cutaneous side effect of isotretinoin. *J Am Acad Dermatol* 1985; **13**: 665.
17. Levin J, Almeyda J. Erythroderma due to etretinate. *Br J Dermatol* 1985; **112**: 373.
18. Mahé E, *et al.* Acitretin-induced erythroderma in a psoriatic patient. *J Eur Acad Dermatol Venereol* 2006; **20**: 1133–4.
19. Burke H, Carmichael AJ. Reversible melasma associated with isotretinoin. *Br J Dermatol* 1996; **135**: 862.
20. Seukeran DC, Cunliffe WJ. The treatment of acne fulminans: a review of 25 cases. *Br J Dermatol* 1999; **141**: 307–9.
21. Huston NR, Mules R. Acne fulminans with severe myalgia precipitated by isotretinoin therapy. *N Z Med J* 1985; **36**: 821.
22. Choi EH, Bang D. Acne fulminans and 13-cis-retinoic acid. *J Dermatol* 1992; **19**: 378–83.
23. Kellett JK, *et al.* Erythema nodosum and circulating immune complexes in acne fulminans after treatment with isotretinoin. *BMJ* 1985; **290**: 820.
24. Tan BB, *et al.* Acne fulminans and erythema nodosum during isotretinoin therapy responding to dapsone. *Clin Exp Dermatol* 1997; **22**: 26–7.
25. Kuo MC, *et al.* All-trans-retinoic acid-induced erythema nodosum in patients with acute promyelocytic leukemia. *Ann Hematol* 2004; **83**: 376–80.
26. McIvor A. Fatal toxic epidermal necrolysis associated with etretinate. *BMJ* 1992; **304**: 548.
27. van der Pijl JW, *et al.* Isotretinoin and azathioprine: a synergy that makes hair curl? *Lancet* 1996; **348**: 622–3.
28. Önder M, *et al.* Isotretinoin-induced nail fragility and onycholysis. *J Dermatol Treat* 2001; **12**: 115–16.
29. Dharmagunawardena B, Charles-Holmes R. Median canaliform dystrophy following isotretinoin therapy. *Br J Dermatol* 1997; **137**: 658–9.
30. Yung A, *et al.* Isotretinoin-induced elonyxis. *Br J Dermatol* 2005; **153**: 671–2.

**Effects on taste.** Almost complete loss of taste has been reported in a patient given oral isotretinoin 600 micrograms/kg daily for 20 weeks.<sup>1</sup> Sense of taste returned about 6 months after isotretinoin was stopped. Up to September 1994 the UK CSM knew of 5 cases of taste changes, including 4 reports of loss of taste.

1. Halpern SM, *et al.* Loss of taste associated with isotretinoin. *Br J Dermatol* 1996; **134**: 378.

**Overdosage.** Apart from vague abdominal discomfort there were no other symptoms or significant abnormalities in a 15-year-old who was treated with gastric lavage 1.5 hours after ingestion of 350 mg of isotretinoin.<sup>1</sup> The authors noted a similar outcome in 2 other cases of isotretinoin overdosage reported in the literature at that time. In a subsequent report, mild headache, skin that was dry and peeling, and cheilitis occurred in a 29-year-old who ingested 900 mg of isotretinoin.<sup>2</sup>

1. Hepburn NC. Deliberate self-poisoning with isotretinoin. *Br J Dermatol* 1990; **122**: 840–1.
2. Aubin S, *et al.* Massive isotretinoin intoxication. *Clin Exp Dermatol* 1995; **20**: 348–50.

**Vasculitic syndromes.** The manufacturer of isotretinoin and etretinate has received isolated reports of vasculitis associated with the use of these oral retinoids; Wegener's granulomatosis has also been reported after the use of isotretinoin.<sup>1,2</sup> The precise mechanism underlying these effects is unknown; in some patients there may have been a direct toxic effect as symptoms developed shortly after the start of treatment, in other patients the

onset was long-delayed and may have been triggered by the incidental use of antibacterials. Vasculitis, manifesting as fever and skin lesions, has been reported in patients given oral tretinoin for acute promyelocytic leukaemia.<sup>3</sup>

1. Dwyer JM, *et al.* Vasculitis and retinoids. *Lancet* 1989; **ii**: 494–6.
2. Anonymous. Retinoids and necrotizing vasculitis. *WHO Drug Inf* 1989; **3**: 187.
3. Paydas S, *et al.* Vasculitis associated with all trans retinoic acid (ATRA) in a case with acute promyelocytic leukemia. *Leuk Lymphoma* 2003; **44**: 547–8.

## Precautions

Isotretinoin and other oral retinoids are teratogenic and therefore contra-indicated in pregnant patients. It is advisable for female patients to begin using contraceptive measures 1 month before starting isotretinoin treatment. Pregnancy should be excluded before starting therapy and avoided during treatment and for 1 month after stopping treatment. Patients receiving isotretinoin should not donate blood during, or for 1 month after stopping therapy, because of the potential risk to the fetus of a pregnant transfusion recipient. *Pregnancy or blood donation must be avoided for much longer periods in patients taking acitretin or etretinate.* Isotretinoin is contra-indicated in patients with hepatic impairment, hyperlipidaemias, and hypervitaminosis A. Renal impairment does not affect the pharmacokinetics of isotretinoin but a lower starting dose has been suggested in severe impairment. It is not known whether isotretinoin is distributed into breast milk but its lipophilicity makes this likely; isotretinoin use in breast-feeding women is therefore contra-indicated because of the potential for adverse effects in the infant. Isotretinoin should be used with care in patients with a history of depression and patients taking isotretinoin should be monitored for signs of depressive illness.

Liver function and fasting blood lipids should be measured at the start of therapy, after the first month (or every 1 to 2 weeks for the first 2 months for acitretin), and thereafter as appropriate. Blood glucose should be monitored throughout treatment in patients who either have, or are predisposed to, diabetes mellitus. Some recommend routine radiological evaluation in patients receiving long-term therapy (see under Effects on the Musculoskeletal System, above). Patients may have a reduced tolerance to contact lenses.

Excessive exposure to sunlight and UV light should be avoided.

Dizziness, drowsiness, and visual disturbances may occur rarely, and could affect the performance of skilled tasks such as driving.

When applied topically the precautions described under tretinoin (see p.1618) should be considered.

**Pregnancy.** The problem of prescribing oral retinoids to women of child-bearing potential has been discussed.<sup>1,2</sup> Intra-uterine exposure to isotretinoin has caused spontaneous abortion and a characteristic pattern of fetal malformations involving craniofacial, cardiac, thymic, and CNS structures.<sup>3,4</sup> Some infants have also shown subnormal intelligence and other neuropsychological impairments.<sup>5</sup> The risk of malformation appears to be high at all therapeutic doses of isotretinoin even when the duration of exposure is short.<sup>6</sup> Despite warnings on the use of retinoids during pregnancy and the need for adequate contraception in women of child-bearing potential, and other strict guidelines on their use, intra-uterine exposure to retinoids has still occurred.<sup>7–10</sup>

Isotretinoin has a relatively short half-life and it has been recommended that conception should be avoided for at least one month after the end of treatment. A survey of women who conceived after the use of isotretinoin (64% within one month of stopping treatment) suggested that the incidence of spontaneous abortion or congenital malformations was no greater than in the general population.<sup>11</sup>

Warnings to avoid conception are similar for oral tretinoin (see p.1618). However, patients taking oral retinoids with longer half-lives must avoid conception for much longer periods; at least 2 years (3 years in the USA) is recommended if patients are taking acitretin although the period of time for patients taking etretinate has not been established (see also Pregnancy under Acitretin, p.1586).

Unless otherwise contra-indicated, oral combined contraceptives have been recommended as the contraceptive method of choice for women undergoing retinoid treatment.<sup>12</sup> Use of an additional

form of contraception, such as a barrier method, is also recommended.<sup>2,7</sup> For further information on the use of hormonal contraceptives with retinoids, see p.2068.

- Mitchell AA. Oral retinoids: what should the prescriber know about their teratogenic hazards among women of child-bearing potential? *Drug Safety* 1992; **7**: 79–85.
- Chan A, et al. Oral retinoids and pregnancy. *Med J Aust* 1996; **165**: 164–7.
- Lammer EJ, et al. Retinoic acid embryopathy. *N Engl J Med* 1985; **313**: 837–41.
- Rosa F. Isotretinoin dose and teratogenicity. *Lancet* 1987; **ii**: 1154.
- Adams J. High incidence of intellectual deficits in 5-year-old children exposed to isotretinoin 'in utero'. *Teratology* 1990; **41**: 614.
- Dai WS, et al. Epidemiology of isotretinoin exposure during pregnancy. *J Am Acad Dermatol* 1992; **26**: 599–606.
- Atanackovic G, Koren G. Fetal exposure to oral isotretinoin: failure to comply with the Pregnancy Prevention Program. *Can Med Assoc J* 1999; **160**: 1719–20.
- CDC. Accutane -exposed pregnancies—California, 1999. *MMWR* 2000; **49**: 28–31.
- Adverse Drug Reactions Advisory Committee (ADRAC). Avoiding fetal abnormalities with isotretinoin. *Aust Adverse Drug React Bull* 2005; **24**: 3. Also available at: <http://www.tga.gov.au/adrb/aadrb0502.htm> (accessed 27/09/07)
- Abroms L, et al. What is the best approach to reducing birth defects associated with isotretinoin? *PLoS Med* 2006; **3**: e483. Available at: <http://medicine.plosjournals.org/perlserv/?request=get-document&doi=10.1371/journal.pmed.0030483> (accessed 27/09/07)
- Dai WS, et al. Safety of pregnancy after discontinuation of isotretinoin. *Arch Dermatol* 1989; **125**: 362–5.
- Lehucher Ceyrac D, et al. Retinoids and contraception. *Dermatology* 1992; **184**: 161–70.

**Skin fragility.** Wax depilation should be avoided in patients receiving retinoids since they cause increased skin fragility and facial and leg erosions have occurred.<sup>1–3</sup> Licensed UK product information also recommends that wax depilation should be avoided for at least 6 months after isotretinoin treatment because of the risk of epidermal stripping. Aggressive chemical dermabrasion and cutaneous laser treatment should also be avoided for a period of 5 to 6 months after treatment because of the risk of hypertrophic scarring in atypical areas and, more rarely, post-inflammatory hypo- or hyperpigmentation in treated areas.

- Egido Romo M. Isotretinoin and wax epilation. *Br J Dermatol* 1991; **124**: 393.
- Holmes SC, Thomson J. Isotretinoin and skin fragility. *Br J Dermatol* 1995; **132**: 165.
- Woolloons A, Price ML. Roaccutane and wax epilation: a cautionary tale. *Br J Dermatol* 1997; **137**: 839–40.

## Interactions

Use of isotretinoin with vitamin A (including dietary supplements) should be avoided because of additive toxic effects. Tetracyclines should be avoided as their use with isotretinoin has been associated with the development of benign intracranial hypertension. Skin irritation may be increased if isotretinoin is given with topical keratolytic or exfoliative anti-acne treatments; such use should be avoided.

**Antiepileptics.** For the effect of isotretinoin on carbamazepine, see p.475.

**Hormonal contraceptives.** For discussion of the potential interactions of retinoids with oral hormonal contraceptives, and the effect this might have on contraceptive choice during retinoid treatment, see p.2068.

## Pharmacokinetics

Isotretinoin is absorbed from the gastrointestinal tract and absorption may be increased by food. Minimal systemic absorption occurs after topical application. Peak plasma concentrations occur 1 to 4 hours after oral doses. Oral bioavailability is low, possibly due to metabolism in the gut wall and first-pass metabolism in the liver. Isotretinoin is highly bound to plasma proteins. It is metabolised in the liver to its major metabolite 4-oxo-isotretinoin; there is also some isomerisation of isotretinoin to tretinoin. Several cytochrome P450 isoenzymes are involved in isotretinoin metabolism, including CYP2C8, CYP2C9, CYP3A4, and CYP2B6. Isotretinoin, tretinoin, and their metabolites undergo enterohepatic recycling. The terminal elimination half-life of isotretinoin is 10 to 20 hours, while that of the 4-oxo metabolite may be up to 50 hours; return to physiological levels of retinoids takes about 2 weeks after stopping therapy. Equal amounts of a dose appear in the faeces, mainly as unchanged drug, and in the urine as metabolites.

Isotretinoin crosses the placenta. It is not known whether isotretinoin is distributed into breast milk but its lipophilicity makes this likely.

## References

- Colburn WA, et al. Food increases the bioavailability of isotretinoin. *J Clin Pharmacol* 1983; **23**: 534–9.
- Lucek RW, Colburn WA. Clinical pharmacokinetics of the retinoids. *Clin Pharmacokinet* 1985; **10**: 38–62.
- Kraft JC, et al. Embryonic retinoid concentrations after maternal intake of isotretinoin. *N Engl J Med* 1989; **321**: 262.
- Larsen FG, et al. Pharmacokinetics and therapeutic efficacy of retinoids in skin diseases. *Clin Pharmacokinet* 1992; **23**: 42–61.
- Chen C, et al. Negligible systemic absorption of topical isotretinoin cream: implications for teratogenicity. *J Clin Pharmacol* 1997; **37**: 279–84.
- Nulman I, et al. Steady-state pharmacokinetics of isotretinoin and its 4-oxo metabolite: implications for fetal safety. *J Clin Pharmacol* 1998; **38**: 926–30.

## Uses and Administration

Isotretinoin is a retinoid. It is the *cis* configuration of tretinoin (p.1618), which is the acid form of vitamin A (p.1971). Isotretinoin is given orally for the treatment of severe acne (below) that has not responded to other measures; it is also applied topically in milder forms of acne. It is not indicated for uncomplicated adolescent acne, and is not licensed for prepubertal acne (but see also Administration in Children, below, for use in infantile acne). Isotretinoin has also been tried in a number of other skin disorders and in some forms of neoplastic disease.

In the UK and a number of other countries the initial oral dose of isotretinoin for acne is 500 micrograms/kg daily, although in the USA initial doses of up to 1 mg/kg daily are permitted. The dose is given with food once daily or in two divided doses and adjusted if necessary up to 1 mg/kg daily according to response and adverse effects. Patients intolerant to the initial dose may be able to continue treatment at a lower dose, but there is a higher risk of relapse. Doses up to 2 mg/kg daily are permitted in the USA and some other countries for patients whose disease is very severe or primarily on the body instead of the face. A lower starting dose has been recommended in the UK for patients with severe renal impairment (see below).

Acute exacerbation of acne is occasionally seen during the initial period, but usually subsides within 7 to 10 days on continued treatment. Treatment should continue for 15 to 24 weeks or until the total cyst count has decreased by over 70%. Long-term remission and relapse rates are related to total dose, and additional benefit is not expected beyond a cumulative dose of 120 to 150 mg/kg. Improvement may continue for several months after stopping treatment; prolonged remissions can occur.

Repeat courses are not normally recommended but occasionally they may be required. However, since acne may continue to improve after stopping isotretinoin, there must be at least a 2-month drug-free period before starting repeat treatment.

For the topical treatment of acne a gel containing 0.05% of isotretinoin is applied sparingly once or twice daily. A therapeutic response may not be evident for 6 to 8 weeks.

## General reviews

- DiGiovanna JJ. Systemic retinoid therapy. *Dermatol Clin* 2001; **19**: 161–7.
- Ellis CN, Krach KJ. Uses and complications of isotretinoin therapy. *J Am Acad Dermatol* 2001; **45** (suppl): S150–S157.
- Vivat-Hannah V, Zusi FC. Retinoids as therapeutic agents: today and tomorrow. *Mini Rev Med Chem* 2005; **5**: 755–60.
- Njar VC, et al. Retinoids in clinical use. *Med Chem* 2006; **2**: 431–8.

**Acne.** The retinoids play an important role in the treatment of acne (p.1577). Isotretinoin reduces sebum excretion with a subsequent reduction in growth of *Propionibacterium acnes*; it also normalises the differentiation of keratinocytes, which has a comedolytic effect, and appears to have a direct anti-inflammatory effect.<sup>1–3</sup> The main indication for oral isotretinoin therapy is severe forms of acne (such as conglobate or nodulocystic acne or acne at risk of permanent scarring) that is unresponsive to other therapy including systemic antibacterials. Some argue,<sup>4,5</sup> however, that oral isotretinoin should be considered for first-line treatment in other cases, such as less severe acne that has the potential to cause scarring or acne that is causing severe psychological distress. Most patients remain free of their disease after a single

course of isotretinoin, or have a mild recurrence that responds to other treatments to which it was previously resistant. A minority will relapse and those at higher risk include patients less than 16 years of age, those with severe acne on the trunk, and adult women.<sup>2</sup> Cumulative dose, rather than daily dose, appears to be an important factor in achieving stable remission.<sup>4</sup> To avoid relapse, a course of therapy to a cumulative dose of 120 to 150 mg/kg is required.<sup>2</sup> This usually equates to a course of 5 to 6 months using daily doses of 0.5 to 1 mg/kg. One group suggests<sup>4</sup> that treatment should be continued for 2 months after complete clearing of acne to avoid recurrence, and that higher cumulative doses (up to 200 mg/kg) might be needed in some cases, such as those showing clear signs of ongoing improvement when a cumulative dose of 150 mg/kg has been reached. In patients who do relapse, repeat courses may be indicated.<sup>2,3</sup> However, improvement may continue for several months after withdrawal and at least 2 months should elapse before determining whether further treatment is necessary. There is evidence to suggest that patients who repeatedly relapse after stopping standard isotretinoin therapy may benefit from continuous use of very low doses of isotretinoin, such as 250 or 500 micrograms/kg daily taken every 4th week for 6 months, 100 micrograms/kg daily, or a single dose of 20 mg once or twice a week.<sup>6</sup> Low-dose regimens have also been tried instead of standard isotretinoin doses for persistent moderate or severe acne. A dose of 20 mg daily for 6 months has produced significant improvement or complete remission in moderate acne.<sup>7</sup> However, prolonged use of low-dose regimens is needed to achieve a cumulative dose of 120 mg/kg and reduce the risk of relapse.<sup>8</sup> Isotretinoin has also been used for the treatment of acne associated with immunosuppressive therapy in transplant recipients.<sup>9,10</sup>

Isotretinoin is also used topically for acne. Although it has no sebostatic effect and only a weak direct anti-inflammatory effect by this route<sup>1</sup> its comedolytic effect makes unplugged follicles less anaerobic, reducing *P. acnes* growth and associated inflammation.<sup>11</sup> Topical isotretinoin appears to have a similar efficacy to tretinoin, but may be better tolerated.<sup>3</sup>

Isotretinoin is not licensed for the treatment of prepubertal acne because of the risk of adverse effects including early epiphyseal closure, but see also Administration in Children, below.

- Gollnick H. Current concepts of the pathogenesis of acne: implications for drug treatment. *Drugs* 2003; **63**: 1579–96.
- James WD. Acne. *N Engl J Med* 2005; **352**: 1463–72.
- Chivot M. Retinoid therapy for acne: a comparative review. *Am J Clin Dermatol* 2005; **6**: 13–19.
- Cooper AJ. The Australian Roaccutane Advisory Board. Treatment of acne with isotretinoin: recommendations based on Australian experience. *Australas J Dermatol* 2003; **42**: 97–105.
- Dréno B, et al. An expert view on the treatment of acne with systemic antibiotics and/or oral isotretinoin in the light of the new European recommendations. *Eur J Dermatol* 2006; **16**: 565–71.
- Palmer RA, et al. 'Microdose' isotretinoin. *Br J Dermatol* 2000; **143**: 205–6.
- Amichai B, et al. Low-dose isotretinoin in the treatment of acne vulgaris. *J Am Acad Dermatol* 2006; **54**: 644–6.
- Mandekou-Lefaki I, et al. Low-dose schema of isotretinoin in acne vulgaris. *Int J Clin Pharmacol Res* 2003; **23**: 41–6.
- Tam M, Cooper A. The use of isotretinoin in a renal transplant patient with acne. *Br J Dermatol* 1987; **116**: 463.
- Bunker CB, et al. Isotretinoin treatment of severe acne in post-transplant patients taking cyclosporine. *J Am Acad Dermatol* 1990; **22**: 693–4.
- Goulden V. Guidelines for the management of acne vulgaris in adolescents. *Pediatr Drugs* 2003; **5**: 301–13.

**Administration in children.** Oral isotretinoin is licensed in most countries for use from 12 years of age where appropriate, but it is not licensed for the treatment of prepubertal acne because of the risk of adverse effects including early epiphyseal closure. However, it has been used orally with some success in nodulocystic infantile acne when topical preparations and antibacterial therapies have not been effective.<sup>1–4</sup> A range of doses have been used, sometimes influenced by the dosage form available, but in general doses have been similar to those used in older patients, that is, 0.5 to 1 mg/kg daily to cumulative doses of 120 to 150 mg/kg. As there are no suitable licensed oral products for children, isotretinoin liquid capsules have been opened and the contents mixed with a drink<sup>1,2</sup> or soft food<sup>3</sup> immediately before use to make administration easier. One report<sup>3</sup> described freezing the capsule so that it could be cut more easily to the required dose, which could then be concealed in food.

For mention of the investigation of isotretinoin in children with neuroblastoma, see Malignant Neoplasms, below.

- Mengesha YM, Hansen RC. Toddler-age nodulocystic acne. *J Pediatr* 1999; **134**: 644–8.
- Sarazin F, et al. Treatment of an infantile acne with oral isotretinoin. *Eur J Dermatol* 2004; **14**: 71–2.
- Barnes CJ, et al. A practical approach for the use of oral isotretinoin for infantile acne. *Pediatr Dermatol* 2005; **22**: 166–9.
- Torrello A, et al. Severe acne infantum successfully treated with isotretinoin. *Pediatr Dermatol* 2005; **22**: 357–9.

**Administration in renal impairment.** Although renal impairment does not affect the pharmacokinetics of isotretinoin, licensed UK product information suggests that patients with severe renal impairment being treated with oral isotretinoin for acne should be started at a lower dose, such as 10 mg daily. It may be gradually increased up to 1 mg/kg daily as tolerated.



**Malignant neoplasms.** Retinoids such as isotretinoin have been studied in the treatment of various neoplastic or preneoplastic disorders. Although oral tretinoin is used for remission induction in acute promyelocytic leukaemia (see p.1619), other retinoids do not have an established role in the treatment of cancer. There may, however, be a place for the use of retinoids in the chemoprevention of some malignancies.

There has been particular interest in the potential for retinoids to prevent the formation of *skin cancers* (p.672) in patients at increased risk. Maintenance immunosuppression may increase the incidence of pre-malignant and malignant skin lesions in solid organ transplant recipients; large numbers of lesions can develop and tend to be more aggressive than those in the general population.<sup>1</sup> Although there has been some investigation in cardiac transplant recipients, most case reports and some small studies have involved renal transplant patients. Oral acitretin has been reported to reduce the number of actinic keratoses and reduce the development of new basal and squamous cell carcinomas in these patients.<sup>1-4</sup> Other patients at increased risk of skin cancers who may benefit from prophylactic retinoid therapy include those with xeroderma pigmentosum and naevoid basal cell carcinoma syndrome; oral isotretinoin, rather than acitretin, has been tried in such patients.<sup>5</sup> Retinoids might also be considered in others who have already developed nonmelanoma skin cancers, such as those with conditions requiring maintenance immunosuppression, chronic lymphocytic leukaemia or non-Hodgkin's lymphoma, severe photodamage of the skin, and those with squamous cell carcinoma at high risk of metastasis or that has already metastasised.<sup>5</sup>

Since retinoids suppress rather than cure skin cancer, rebound occurs when the retinoid is stopped and long-term therapy is needed. There is some concern about the risks of such long-term use, particularly on plasma lipids and bone, and monitoring has been recommended.<sup>1,4,5</sup> The mucocutaneous adverse effects that commonly occur can affect patient acceptance during long-term use; mucocutaneous effects may be more severe with isotretinoin, but hair loss may be more extensive with acitretin.<sup>4,5</sup> Gradual dose escalation to an effective dose can be used to minimise these mucocutaneous effects. One example using isotretinoin starts with a dose of 250 micrograms/kg on alternate days for a month, increased to 250 micrograms/kg daily for the second month, then to 500 micrograms/kg daily for the third month; the dose is then adjusted as tolerated.<sup>7</sup> As there are risks of teratogenicity with retinoids, isotretinoin is preferred for women of child-bearing potential because of its shorter half-life.<sup>4,5</sup> For acitretin doses that have been used, see p.1586.

Topical application of retinoids has also been tried for chemoprevention of skin cancers. Topical tretinoin has been used on actinic keratoses in organ transplant recipients, but results have been mixed and may depend on dose. If squamous cell carcinomas are present, however, systemic retinoids should be considered.<sup>3</sup>

Retinoids have been studied in the chemoprevention of primary disease recurrence and second primary tumours after treatment for *squamous cell carcinoma of the head and neck* (p.666) but results have been mixed and limited by resistance and toxicity.<sup>6</sup> A large placebo-controlled study<sup>7</sup> has also reported that low-dose oral isotretinoin (30 mg daily for 3 years with an additional 4 years of follow-up) did not reduce the rate of second primary tumours or death in patients who had been treated for early stage head and neck squamous cell carcinoma. There has also been some interest in the use of retinoids, given orally (isotretinoin) or topically (isotretinoin or tretinoin), in the management of *oral leucoplakia*, which can be pre-malignant (see under Bleomycin, p.688). However, despite reports of beneficial response, relapse frequently occurs on stopping retinoid therapy.<sup>6,8</sup>

Oral isotretinoin has been studied as continuation therapy in children with high-risk *neuroblastoma* that had responded to intensive chemotherapy. One study<sup>9</sup> found improved survival with 6 cycles of isotretinoin given for 14 days of each 28-day cycle. However, another study<sup>10</sup> using a lower dose given daily for 4 years or until relapse found no additional benefit from isotretinoin.

- Kovach BT, *et al.* Systemic strategies for chemoprevention of skin cancers in transplant recipients. *Clin Transplant* 2005; **19**: 726-34.
- Chen K, *et al.* Oral retinoids for the prevention of skin cancers in solid organ transplant recipients: a systematic review of randomized controlled trials. *Br J Dermatol* 2005; **152**: 518-23.
- Neuhauss IM, Tope WD. Practical retinoid chemoprophylaxis in solid organ transplant recipients. *Dermatol Ther* 2005; **18**: 28-33.
- Campbell RM, DiGiovanna JJ. Skin cancer chemoprevention with systemic retinoids: an adjunct in the management of selected high-risk patients. *Dermatol Ther* 2006; **19**: 306-14.
- Otley CC, *et al.* Chemoprevention of nonmelanoma skin cancer with systemic retinoids: practical dosing and management of adverse effects. *Dermatol Surg* 2006; **32**: 562-8.
- Smith W, Saba N. Retinoids as chemoprevention for head and neck cancer: where do we go from here? *Crit Rev Oncol Hematol* 2005; **55**: 143-52.
- Khuri FR, *et al.* Randomized phase III trial of low-dose isotretinoin for prevention of second primary tumors in stage I and II head and neck cancer patients. *J Natl Cancer Inst* 2006; **98**: 441-50.
- Gorsky M, Epstein JB. The effect of retinoids on premalignant oral lesions: focus on topical therapy. *Cancer* 2002; **95**: 1258-64.

- Matthay KK, *et al.* Treatment of high-risk neuroblastoma with intensive chemotherapy, radiotherapy, autologous bone marrow transplantation, and 13-cis-retinoic acid. *N Engl J Med* 1999; **341**: 1165-73.
- Kohler JA, *et al.* A randomized trial of 13-cis-retinoic acid in children with advanced neuroblastoma after high-dose therapy. *Br J Cancer* 2000; **83**: 1124-7.

**Skin disorders.** Apart from its established role in the treatment of acne (above), isotretinoin has been tried in many other skin disorders not responding to usual therapy.<sup>1,2</sup> Clinical responses to oral isotretinoin have been reported<sup>1</sup> in small numbers of patients with anogenital warts (p.1584), rosacea (p.1583), and lichen planus (p.1580). Benefit has also been reported for keratinisation disorders such as Darier's disease<sup>2</sup> (p.1578), ichthyosis<sup>1,2</sup> (p.1580), and pityriasis rubra pilaris.<sup>1,2</sup> Isotretinoin is less effective than other retinoids for psoriasis<sup>1</sup> (p.1583). Oral isotretinoin may be used for chemoprevention of skin cancers (see Malignant Neoplasms, above).

Topical isotretinoin has been used to reduce some of the signs of photoaging<sup>3</sup> (p.1581).

- Akyl M, Özgelik S. Non-acne dermatologic indications for systemic isotretinoin. *Am J Clin Dermatol* 2005; **6**: 175-84.
- Sehgal VN, *et al.* Isotretinoin – unapproved indications/uses and dosage: a physician's reference. *Int J Dermatol* 2006; **45**: 772-7.
- Stratigos AJ, Katsambas AD. The role of topical retinoids in the treatment of photoaging. *Drugs* 2005; **65**: 1061-72.

## Preparations

**BP 2008:** Isotretinoin Capsules; Isotretinoin Gel;  
**USP 31:** Isotretinoin Capsules.

**Proprietary Preparations** (details are given in Part 3)

**Arg:** Atlacne; Curacne; Isotrex; Retinide; Roaccutan; Scheritonin; Zonatan; **Austral:** Accure; Isohexal; Isotrex; Oratane; Roaccutane; **Austria:** Ciscutan; Isocutan; Isosol; Lurantal; Roaccutan; **Belg:** Isosupra Lidose; Roaccutane; **Braz:** Acnil; Cecnoin; Isoacne; Isoface; Isotrex; Lurantal; Roaccutan; **Canad:** Accutane; Clarus; Isotrex; **Chile:** Acnotin; Isotrex; Lisacne; Pilex; Roaccutan; **Cz:** Aknenormin; Curacne; Isotretin; Isotrex; Roaccutane; Stiefel Acne Gel; **Denm:** Accutin; Dermaoral; Isotrex; Roaccutan; **Fin:** Roaccutan; **Fr:** Contracne; Curacne; Procuta; Roaccutane; **Ger:** Aknefug Iso; Aknenormin; Isoderm; Isotrex; Isotrex; Roaccutan; **Gr:** A-Cnotren; Accuran; Acnogen; Aknesil; Curacne; Dermoinin; Filtrion; Isotrin; Isodermal; Isogel; Isoskin; Isotroin; Lyotret; Noltron; Noroseptan; Novacne; Opidan; Polican; Reducar; Roaccutane; Stiefotrex; Trefican; Tretin; **Hong Kong:** Acnotin; Isotrex; Oratane; Roaccutane; **Hung:** Aknenormin; Isotrex; Roaccutan; Sotret; Tretinak; **India:** Acutret; Isotroin; **Irl:** Isotrex; Roaccutane; **Israel:** Curatane; Isotrex; Roaccutane; **Ital:** Aisokin; Isotrex; Roaccutan; **Malaysia:** Acnotin; Isotrex; Nimegen; Oratane; Roaccutane; **Mex:** Isoface; Isotrex; Neotrex; Oratane; Roaccutan; Sotret; **Neth:** Roaccutan; **NZ:** Isotrex; Isotrex; Oratane; Roaccutan; **Philipp:** Acnetrex; Isotrex; Roaccutane; **Pol:** Aknenormin; Curacne; Isotrex; Isotek; Roaccutan; Tretinex; **Port:** Isidben; Isoprotol; Isotrex; Orotrex; Roaccutan; **S.Afr:** Acnetane; Isotrex; Oratane; Roaccutan; **Singapore:** Acnotin; Isotrex; Nimegen; Oratane; Roaccutan; **Spain:** Acnemin; Dercutane; Farmacne; Flexresan; Isidben; Iso Estded; Isotrex; Roaccutan; **Switz:** Curacne; Liderna; Roaccutane; Tretinac; **Thai:** Acnotin; Isotane; Isotrex; Proacne; Roaccutan; Sotret; **Turk:** Roaccutan; **UK:** Isotrex; Roaccutan; **USA:** Accutane; Amnesteem; Claravis; Sotret; **Venez:** Cuticlin; Isoface; Isotrex; Roaccutan.

**Multi-ingredient:** **Austria:** Isotrex; Isotrexin; **Braz:** Isotrexin; Isotrexol; **Cz:** Isotrexin; **Fr:** Antibiotrex; **Ger:** Isotrexin; **Hung:** Isotrexin; **Irl:** Isotrexin; **Ital:** Isotrexin; **Pol:** Isotrexin; **Port:** Isotrexin; **Singapore:** Isotrexin; **Spain:** Isotrex Entromicina; **Thai:** Isotrexin; **UK:** Isotrexin.

## Keluamid

Keluamida.

Келуамид

**Profile**

Keluamid has keratolytic properties and has been used in topical preparations for the treatment of seborrhoeic dermatitis and other scaling skin disorders.

## Preparations

**Proprietary Preparations** (details are given in Part 3)

**Arg:** Kelual; **Fr:** Kelual.

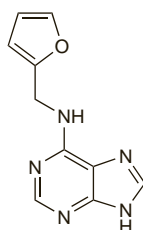
**Multi-ingredient:** **Arg:** Kelual Zinc; **Fr:** Kelual DS; Kelual Zinc; Kertyol-S.

## Kinetin

N<sup>6</sup>-Furfuryladenine; 6-Furfurylamino-purine.

КИНЕТИН

C<sub>10</sub>H<sub>9</sub>N<sub>5</sub>O = 215.2.  
CAS — 525-79-1.



NOTE: The name kinetin has also been used as a proprietary name for hyaluronidase (p.2321).

## Profile

Kinetin is a plant growth hormone that has been promoted in products for the management of photodamaged skin and hyperpigmentation but good evidence of efficacy appears to be lacking.

## Preparations

**Proprietary Preparations** (details are given in Part 3)

**Arg:** Kinerase†; **Braz:** Kinerase; **Hong Kong:** Kinerase; **Malaysia:** Kinerase†; **Mex:** Kinerase; **Singapore:** Kinerase; **USA:** Kinerase.

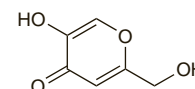
## Kojic Acid

Kójico, ácido. 5-Hydroxy-2-hydroxymethyl-4-pyrone.

Койевая Кислота

C<sub>6</sub>H<sub>6</sub>O<sub>4</sub> = 142.1.

CAS — 501-30-4.



## Profile

Kojic acid is reported to inhibit melanin production and is used in topical preparations for the treatment of hyperpigmentation disorders (p.1582). Kojic acid is also used as a food additive.

## References

- Lim JT. Treatment of melasma using kojic acid in a gel containing hydroquinone and glycolic acid. *Dermatol Surg* 1999; **25**: 282-4.

## Preparations

**Proprietary Preparations** (details are given in Part 3)

**Chile:** Unitone 4.

**Multi-ingredient:** **Arg:** Cellskinlab Phyto Spot; Melasoft†; Neoquin; **Braz:** Melani-D Maos; **Chile:** Elastik†; D 4†; Neostrata; Phyto Spot; Primacy Phyto ††; **Mex:** Nova Derm; **Port:** Despigmentante; Fade Cream†.

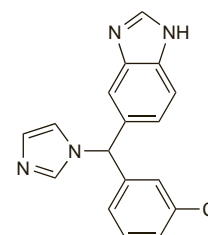
## Liarozole (BAN, rINN)

Liarozol; Liarozolum. (±)-5-(m-Chloro-α-imidazol-1-ylbenzyl)benzimidazole.

Лиарозол

C<sub>17</sub>H<sub>13</sub>ClN<sub>4</sub> = 308.8.

CAS — 115575-11-6; 145858-51-1.



## Liarozole Fumarate (BANM, USAN, rINN)

Fumarato de liarozol; Liarozole, Fumarate de; Liarozoli Fumaras; R-85246.

Лиарозола Фумарат

2C<sub>17</sub>H<sub>13</sub>ClN<sub>4</sub>·3C<sub>4</sub>H<sub>4</sub>O<sub>4</sub> = 965.7.

CAS — 145858-52-2.

## Liarozole Hydrochloride (BANM, USAN, rINN)

Hidrocloruro de liarozol; Liarozole, Chlorhydrate de; Liarozoli Hydrochloridum; R-75251.

Лиарозола Гидрохлорид

C<sub>17</sub>H<sub>13</sub>ClN<sub>4</sub>·HCl = 345.2.

CAS — 145858-50-0.

## Profile

Liarozole, an imidazole analogue, increases plasma and cutaneous retinoic acid concentrations through inhibition of cytochrome P450 isoenzymes involved in retinoic acid catabolism. It is under investigation for the management of ichthyoses and psoriasis.

## References

- Bhushan M, *et al.* Oral liarozole in the treatment of palmoplantar pustular psoriasis: a randomized, double-blind, placebo-controlled study. *Br J Dermatol* 2001; **145**: 546-53.
- Lucker GPH, *et al.* Topical liarozole in ichthyosis: a double-blind, left-right comparative study followed by a long-term open maintenance study. *Br J Dermatol* 2005; **152**: 566-9.
- Verfaillie CJ, *et al.* Oral liarozole vs. acitretin in the treatment of ichthyosis: a phase II/III multicentre, double-blind, randomized, active-controlled study. *Br J Dermatol* 2007; **156**: 965-73.

The symbol † denotes a preparation no longer actively marketed