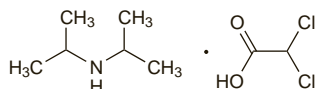


pressan; **India:** Nepresol; **Malaysia:** Nepresol†; **S.Afr.:** Nepresol†; **Swed.:** Nepresol†; **Switz.:** Nepresol†; **Thal.:** Nepresol.

**Multi-ingredient:** **Braz.:** Adelfan-Esidx†; **Ger.:** Adelfan-Esidx†; Obslazin N†; Tri-Torr†; Triniton; **Hong Kong:** Adelfan-Esidx; **India:** Adelfan; Adelfan-Esidx; Beptazine; Beptazine-H; **Indon.:** Dellasidrex; **Rus.:** Adelfan-Esidx (Адельфан-эсидрек); Triresid K (Трирезид К); **Spain:** Adelfan-Esidx†; **Switz.:** Adelfan-Esidx; **Turk.:** Adelfan; Adelfan-Esidx.

## Di-isopropylammonium Dichloroacetate

Diisopropylamina, didoroacetato de; Di-isopropylamine Dichloroacetate; Di-isopropylamine Dichloroethanoate; DIPA-DCA.  $C_8H_{17}Cl_2NO_2 = 230.1$ . CAS — 660-27-5.



## Profile

Di-isopropylammonium dichloroacetate is a vasodilator that has been given in peripheral and cerebral vascular disorders. Preparations containing it have sometimes been described as 'pangamic acid' (p.2362).

## Preparations

**Proprietary Preparations** (details are given in Part 3)

**Ger.:** Disotat†; Oxypanam†; **Mex.:** Ditrei.

**Multi-ingredient:** **Hong Kong:** Liverall†; **Spain:** Vitaber A E.

## Dilazep Hydrochloride (rINN)

Asta C-4898; Dilazep, Chlorhydrate de; Dilazepi Hydrochloridum; Hidrocloruro de dilazep. Perhydro-1,4-diazepin-1,4-diylbis(trimethylene 3,4,5-trimethoxybenzoate) dihydrochloride.

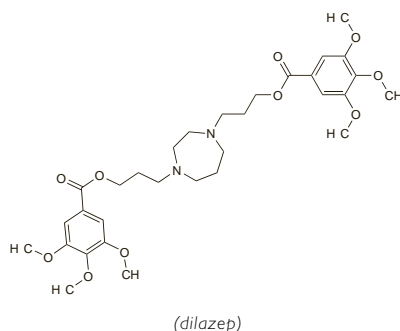
Дилязеп Гидрохлорид

$C_{31}H_{44}N_2O_{10} \cdot 2HCl = 677.6$ .

CAS — 35898-87-4 (dilazep); 20153-98-4 (dilazep hydrochloride).

ATC — C01DX10.

ATC Vet — QC01DX10.



(dilazep)

**Pharmacopoeias.** *Jpn* includes the monohydrate.

## Profile

Dilazep hydrochloride is a vasodilator that is used in ischaemic heart disease.

## Preparations

**Proprietary Preparations** (details are given in Part 3)

**India:** Cornelian; **Jpn:** Cornelian.

## Diltiazem Hydrochloride

(BANM, USAN, rINN)

CRD-401; Diltiazemihydroklorid; Diltiazem, chlorhydrate de; Diltiazem Hidroklorür; Diltiazem hydrochlorid; Diltiazem-hidroklorid; Diltiazemihydroklorid; Diltiazemi hydrochloridum; Diltiazemo hidrochloridas; Diltiazemu chlorowodorek; Hidrocloruro de diltiazem; Latiazem Hydrochloride; MK-793 (diltiazem malate). (+)-cis-3-Acetoxy-5-(2-dimethylaminoethyl)-2,3-dihydro-2-(4-methoxyphenyl)-1,5-benzothiazepin-4(5H)-one hydrochloride; (2S,3S)-5-(2-Dimethylaminoethyl)-2,3,4,5-tetrahydro-2-(4-methoxyphenyl)-4-oxo-1,5-benzothiazepin-3-yl acetate hydrochloride.

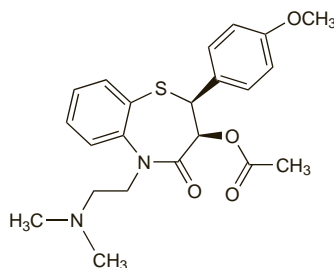
Дилтиазема Гидрохлорид

$C_{22}H_{26}N_2O_5 \cdot HCl = 451.0$ .

CAS — 42399-41-7 (diltiazem); 33286-22-5 (diltiazem hydrochloride); 144604-00-2 (diltiazem malate).

ATC — C08DB01.

ATC Vet — QC08DB01.



(diltiazem)

**Pharmacopoeias.** In *Chin.*, *Eur.* (see p.vii), *Jpn.*, and *US*.

**Ph. Eur. 6.2** (Diltiazem Hydrochloride). A white or almost white, crystalline powder. Freely soluble in water, in dichloromethane, and in methyl alcohol; slightly soluble in dehydrated alcohol. The pH of a 1% solution in water is 4.3 to 5.3. Store in airtight containers. Protect from light.

**USP 31** (Diltiazem Hydrochloride). A white, odourless, crystalline powder, or small crystals. Freely soluble in water, in chloroform, in formic acid, and in methyl alcohol; sparingly soluble in dehydrated alcohol; insoluble in ether. Store in airtight containers. Protect from light.

## Adverse Effects

Treatment with diltiazem is generally well tolerated. Headache, ankle oedema, hypotension, dizziness, flushing, fatigue, and nausea and other gastrointestinal disturbances (including anorexia, vomiting, constipation or diarrhoea, taste disturbances, and weight gain) may occur. Gingival hyperplasia has been reported. Rashes, possibly due to hypersensitivity, are normally mild and transient, but in a few cases erythema multiforme or exfoliative dermatitis has developed; photosensitivity reactions may also occur. Transient elevations in liver enzyme values, and occasionally hepatitis, have been reported.

Diltiazem may depress cardiac conduction and has occasionally led to AV block, bradycardia, and rarely asystole or sinus arrest.

Overdosage with diltiazem may be associated with bradycardia, with or without AV conduction defects, and hypotension.

Diltiazem has been shown to cause teratogenicity in animal studies.

**Effects on mortality.** For discussion of the possibility that calcium-channel blockers might be associated with increased cardiovascular mortality, see under Adverse Effects of Nifedipine, p.1350.

**Angioedema.** Periorbital angioedema, accompanied by pruritus or burning and erythema developed in 2 patients given diltiazem.<sup>1</sup>

1. Sadick NS, *et al.* Angioedema from calcium channel blockers. *J Am Acad Dermatol* 1989; **21**: 132-3.

**Effects on the blood.** Thrombocytopenia has been reported in association with diltiazem.<sup>1,2</sup>

1. Lahav M, Arav R. Diltiazem and thrombocytopenia. *Ann Intern Med* 1989; **110**: 327.

2. Michalets EL, Jackson DV. Diltiazem-associated thrombocytopenia. *Pharmacotherapy* 1997; **17**: 1345-8.

**Effects on carbohydrate metabolism.** Although raised blood-glucose concentrations and insulin requirements have been reported<sup>1</sup> in a patient with type 1 diabetes mellitus during diltiazem therapy, particularly at high doses, a study<sup>2</sup> in 11 obese black women, who were nondiabetic but had a family history of type 2 diabetes, failed to find any effect of diltiazem 240 mg daily on plasma-glucose and C-peptide concentrations, nor any clinical signs of glucose intolerance.

1. Pershadsingh HA, *et al.* Association of diltiazem therapy with increased insulin resistance in a patient with type 1 diabetes mellitus. *JAMA* 1987; **257**: 930-1.

2. Jones BJ, *et al.* Effects of diltiazem hydrochloride on glucose tolerance in persons at risk for diabetes mellitus. *Clin Pharm* 1988; **7**: 235-8.

**Effects on the ears.** There have been isolated reports<sup>1</sup> of tinnitus associated with several calcium-channel blockers including nifedipine, nicardipine, nitrendipine, diltiazem, verapamil, and cinarizine.

1. Narváez M, *et al.* Tinnitus with calcium-channel blockers. *Lancet* 1994; **343**: 1229-30.

**Effects on the gastrointestinal tract.** Gastrointestinal disturbances including nausea, vomiting, and constipation, may occur with calcium-channel blockers. A case<sup>1</sup> of intestinal pseudo-

obstruction was reported in a 74-year-old neutropenic man receiving chemotherapy for leukaemia after diltiazem was added to treat new-onset atrial fibrillation. A diagnosis of neutropenic enterocolitis was ruled out and symptoms resolved when diltiazem was stopped; it was concluded that diltiazem was the probable cause.

A similar case attributed to verapamil<sup>2</sup> has been reported.

1. Young RP, Wu H. Intestinal pseudo-obstruction caused by diltiazem in a neutropenic patient. *Ann Pharmacother* 2005; **39**: 1749-51.

2. Schultz HS, Vernon B. Intestinal pseudo-obstruction related to using verapamil. *West J Med* 1989; **151**: 556-8.

**Effects on the heart. AV BLOCK.** AV block appears to be uncommon in patients receiving diltiazem, but is potentially serious when it occurs. Prescription-event monitoring<sup>1</sup> of a cohort of 10 119 patients for 1 year revealed 22 reports of AV block during diltiazem treatment. At least 8 patients had third-degree heart block, and 12 required a pacemaker; 3 died within 72 hours of the onset of heart block. A high proportion of these patients were also receiving beta blockers, which is in line with other reports.<sup>2,3</sup> (See also Beta Blockers under Interactions, below.) There is some evidence that the incidence of this effect may depend on the serum concentration of diltiazem. In a study<sup>4</sup> in patients receiving diltiazem after myocardial infarction, patients with serum-diltiazem concentrations greater than 150 nanograms/mL were more likely to experience AV block than patients with concentrations of diltiazem below this value.

1. Waller PC, Inman WHW. Diltiazem and heart block. *Lancet* 1989; **i**: 617.

2. Hossack KF. Conduction abnormalities due to diltiazem. *N Engl J Med* 1982; **307**: 953-4.

3. Ishikawa T, *et al.* Atrioventricular dissociation and sinus arrest induced by oral diltiazem. *N Engl J Med* 1983; **309**: 1124-5.

4. Nattel S, *et al.* Determinants and significance of diltiazem plasma concentrations after acute myocardial infarction. *Am J Cardiol* 1990; **66**: 1422-8.

**MYOCARDIAL INFARCTION.** Results from at least one large multicentre study (the Multicenter Diltiazem Postinfarction Trial) suggest that diltiazem, although apparently of benefit after myocardial infarction in patients with normal left ventricular function (as indicated by absence of pulmonary congestion), was associated with an increased risk of cardiac death or non-fatal re-infarction in patients with impaired left ventricular function.<sup>1</sup> Long-term follow-up<sup>2</sup> indicated that diltiazem also increased the risk of late-onset heart failure in postinfarction patients with left ventricular dysfunction.

1. The Multicenter Diltiazem Postinfarction Trial Research Group. The effect of diltiazem on mortality and reinfarction after myocardial infarction. *N Engl J Med* 1988; **319**: 385-92.

2. Goldstein RE, *et al.* Diltiazem increases late-onset congestive heart failure in postinfarction patients with early reduction in ejection fraction. *Circulation* 1991; **83**: 52-60.

**WITHDRAWAL.** Life-threatening coronary vasospasm, which was fatal in one patient, occurred in 4 patients after coronary revascularisation for unstable angina.<sup>1</sup> Treatment with a calcium-channel blocker (diltiazem or nifedipine) had been discontinued between 8 and 18 hours before the procedure and this abrupt withdrawal was thought to be responsible for the rebound vasospasm. The coronary vasospasm was managed with glyceryl trinitrate and nifedipine.

Withdrawal of diltiazem over a 4-day period from a patient with stable angina pectoris was followed by recurrence of anginal attacks.<sup>2</sup> Ambulatory ECG monitoring confirmed worsening myocardial ischaemia that responded to re-introduction of diltiazem. Two further patients had a similar withdrawal effect.

1. Engelman RM, *et al.* Rebound vasospasm after coronary revascularization in association with calcium antagonist withdrawal. *Ann Thorac Surg* 1984; **37**: 469-72.

2. Subramanian VB, *et al.* Calcium antagonist withdrawal syndrome: objective demonstration with frequency-modulated ambulatory ST-segment monitoring. *BMJ* 1983; **286**: 520-1.

**Effects on the kidneys.** Diltiazem may be of benefit in various kidney disorders (see under Uses, below). However, there are a few reports of acute renal failure associated with diltiazem use.<sup>1,2</sup> Acute interstitial nephritis has been proposed as a mechanism.<sup>2,3</sup>

1. ter Wee PM, *et al.* Acute renal failure due to diltiazem. *Lancet* 1984; **ii**: 1337-8.

2. Abadín JA, *et al.* Probable diltiazem-induced acute interstitial nephritis. *Ann Pharmacother* 1998; **32**: 656-8.

3. Achenbach V, *et al.* Acute renal failure due to diltiazem. *Lancet* 1985; **i**: 176.

**Effects on mental function.** By September 1989, the WHO collaborative programme for international drug monitoring had gathered 8 cases of mental depression (severe in 2) associated with diltiazem therapy.<sup>1</sup> Time of onset of symptoms varied from a few hours to a few months after starting treatment with diltiazem. There was some evidence that the problem might be dose-related as 5 of the 8 cases were receiving doses of 180 mg daily or more.

Psychoses have been reported rarely in association with diltiazem. A patient<sup>2</sup> who developed hallucinations (both auditory and visual) and paranoid delusions after 2 days of diltiazem therapy was subsequently treated with nifedipine without abnormal effects. Another patient<sup>3</sup> with bipolar affective disorder that had been well-controlled by lithium carbonate for some years developed acute psychosis with extrapyramidal symptoms of cog-

The symbol † denotes a preparation no longer actively marketed