

ethinylestradiol 10 to 20 micrograms (days 5 to 25). Alternatively, cyproterone acetate 25 to 50 mg daily may be added to the first 10 days of any low-dose combined oral contraceptive. When a satisfactory response has been achieved, the cyproterone dosage is gradually reduced, and eventually the low-dose combination preparation may be sufficient.

In some countries spironolactone is the drug of choice for the treatment of hirsutism, particularly if there is associated obesity and hypertension; doses of 100 to 200 mg daily are generally used.^{1,2,4} Despite its wide use, however, evidence of benefit is considered scanty.⁵ *Flutamide*, *finasteride*, and *leuporelin* have also been shown to be effective, although some consider finasteride to be less active.⁴ The condition has also been reported to respond to *ketoconazole*. *Eflornithine* is used typically for the reduction of facial hair.^{1,3,4} It is thought to slow hair growth by the inhibition of ornithine decarboxylase in hair follicles.

Corticosteroids can suppress adrenal androgen production, but results with *dexamethasone* have been disappointing and the addition of an anti-androgen is usually needed.⁴ Corticosteroids may have a limited role in managing hirsutism associated with congenital adrenal hyperplasia.^{1,2}

- Rosenfield RL. Hirsutism. *N Engl J Med* 2005; **353**: 2578–88.
- Claman P, et al. Society of Obstetricians and Gynaecologists of Canada. SOGC clinical practice guidelines no. 110. January 2002: Hirsutism: evaluation and treatment. *J Obstet Gynaecol Can* 2002; **24**: 62–7. Also available at: <http://www.sogc.org/guidelines/public/110E-CPG-January2002.pdf> (accessed 27/06/08)
- Moggetti P, Toscano V. Treatment of hirsutism and acne in hyperandrogenism. *Best Pract Res Clin Endocrinol Metab* 2006; **20**: 221–34.
- Carmina E. A risk-benefit assessment of pharmacological therapies for hirsutism. *Drug Safety* 2001; **24**: 267–76.
- Farquhar C, et al. Spironolactone versus placebo or in combination with steroids for hirsutism and/or acne. Available in The Cochrane Database of Systematic Reviews; Issue 4. Chichester: John Wiley; 2003 (accessed 27/06/08).

Precocious puberty. Although cyproterone acetate has been used for the treatment of central precocious puberty (p.2081), it has generally been superseded and is now given in a short course to prevent the initial stimulatory effect of gonadorelin analogue therapy. The use of an oral dose of cyproterone acetate 50 mg twice daily, given from 3 weeks before to 2 weeks after starting the gonadorelin analogue, has been reported.¹ Menstrual-like bleeding may occur in girls after stopping cyproterone, depending on the degree of precocity. Gonadorelin analogue therapy does not control adrenal production of sex hormones, which, if overactive, can stimulate adrenarche and advancement of bone age; cyproterone acetate in usual doses of 10 to 20 mg twice daily has been used to treat this.¹

Cyproterone acetate may sometimes be used to suppress sexual maturation in the management of peripheral forms of precocious puberty. Although it is not licensed for this, the *BNFC* includes an initial oral dose of 25 mg twice daily, adjusted according to response.

- Laron Z, Kauli R. Experience with cyproterone acetate in the treatment of precocious puberty. *J Pediatr Endocrinol Metab* 2000; **13** (suppl): 805–10.

Preparations

BP 2008: Cyproterone Tablets.

Proprietary Preparations (details are given in Part 3)

Arg.: Androcur; Androst; Asidun; Asoteron; Ceperater; Cidamili; Ciprofarma; Ciproplex; CPD; Kebirterona; Omnigeriat; Purfil; Rubidox; **Aust.:** Androcur; Androst; Androsteron; Androsteron; Bioteron; Ceteron; Ciprostat; **Canad.:** Alt-CPA; Androcur; **Chile:** Ciprovirol; **Cz.:** Androcur; Ciproplex; Minerva; **Denn.:** Androcur; **Fin.:** Androcur; **Fr.:** Androcur; Kallale; **Ger.:** Androcur; Vinitil; **Gr.:** Androcur; **Hong Kong:** Androcur; **Hung.:** Androcur; **Indon.:** Androcur; **Irl.:** Androcur; **Israel:** Androcur; **Armocur;** Ciprostat; **Ital.:** Androcur; **Malaysia:** Androcur; **Cyproplex;** **Mex.:** Androcur; Neoproxil; **Neth.:** Androcur; Curandron; **Norw.:** Androcur; **NZ:** Androcur; **Port.:** Androcur; **Philipp.:** Androcur; **Pol.:** Androcur; **Port.:** Androcur; **Rus.:** Androcur (Андроксип); **S.Afr.:** Androcur; **Cyproplex;** **Singapore:** Androcur; **Spain:** Androcur; **Swed.:** Androcur; **Diane;** **Switz.:** Androcur; Eleacnelle; **Thai.:** Androcur; **Turk.:** Androcur; **UK:** Androcur; **Cyprostat;** **Venez.:** Androcur; Asoteron.

Multi-ingredient: **Arg.:** Avancel; Biofem 35; Climeine; Diane; Mileva; **Aust.:** Brenda-35 ED; Climeine; Diane; Estelle; Juliet; **Austria:** Belgyn; Climeine; Dialuna; Diane; Femogyn; Midiane; Minerva; Sterigynon; Xylia; **Belg.:** Claudia; Climeine; Co-Cyproterone; Cyprodiol; Daphne; Diane; Doc-cyproestra; Gratiella; Merckelisa; Ratiopharmeva; **Braz.:** Artemidis; Cip-rane; Climeine; Diane; Elamax; Ferane 35; Repopil; Selene; Tess; **Canad.:** Diane; **Chile:** Anuar; Climeine; Diane; Dixi-35; Drina; Evilin; Lady-Ten 35; **Cz.:** Chloee; Climeine; Diane; Vreya; **Denn.:** Climeine; Diane; Dianova; Feminil; **Fin.:** Cypretyl; Diane; Femilar; **Fr.:** Climeine; Diane; Evepar; Holgyeme; Lumalia; Minerva; **Ger.:** Attempta; Bella; Clevia; Climeine; Cyproderm; Cypronette; Diane; Ergalea; Juliette; **Gr.:** Gynofen 35; **Hong Kong:** Climeine 28; Diane; **Hung.:** Climeine; Cypromin; Diane; Minerva; Diane; Ginette; **Indon.:** Climeine 28; Diane; **Irl.:** Climeine; **Israel:** Diane; Estelle; **Ital.:** Climeine; Pausene; Visofid; **Malaysia:** Climeine; Diane; Estelle; **Mex.:** Climeine; Diane; Eunice 35-ED; Mileva; **Neth.:** Climeine; Diane; **Norw.:** Climeine; **NZ:** Diane; Estelle; **Philipp.:** Althea; Climeine 28; Diane; **Pol.:** Climeine; Cyprest; Diane; **Port.:** Climeine; Diane; **Rus.:** Climeine (Климеин); Di-ane (Авалане); **S.Afr.:** Climeine; Diane; Diva; Ginette; Minerva; **Singapore:** Climeine; Diane; Estelle; **Spain:** Climeine; Clisin; **Switz.:** Climeine; Cyp-estra; Diane; Feminac; Minerva; **Thai.:** Climeine; Diane; Helen; Lady-35; Manoane; Premet; Sucee; **Turk.:** Climeine; Diane; **UK:** Acnocrin; Cicafem; Clairette; Dianeette; Diva; **Venez.:** Climeine; Diane; Dixi.

Danazol (BAN, USAN, pINN) ⚡

Danatsoli; Danazolium; Win-17757. 17 α -Pregna-2,4-dien-20-yno[2,3-*d*]isoxazol-17 β -ol.

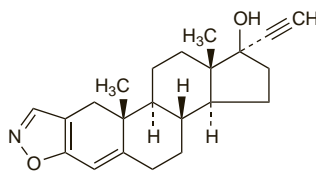
Даназол

C₂₂H₂₇NO₂ = 337.5.

CAS — 17230-88-5.

ATC — G03XA01.

ATC Vet — QG03XA01.



Pharmacopoeias. In *Chin.* and *US*.

USP 31 (Danazol). A white to pale yellow crystalline powder. Practically insoluble or insoluble in water and in petroleum spirit; sparingly soluble in alcohol and in benzene; soluble in acetone; freely soluble in chloroform; slightly soluble in ether. Store in airtight containers. Protect from light.

Adverse Effects

Adverse effects of danazol that reflect inhibition of the pituitary-ovarian axis include menstrual disturbances and amenorrhoea (occasionally persistent), hot flushes, sweating, reduction in breast size, changes in libido, vaginal dryness and irritation, emotional lability, and nervousness.

Adverse effects attributable to androgenic activity include acne, oily skin or hair, mild hirsutism, oedema, weight gain, deepening of the voice, androgenic alopecia, and rarely clitoral hypertrophy. Testicular atrophy and a reduction in spermatogenesis may occur.

Other adverse effects include gastrointestinal disturbances, increased or decreased blood cell counts, thrombotic events, headache, backache, dizziness, tremor, depression, fatigue, sleep disorders, muscle spasm or cramp, skin rash, hyperglucagonaemia, abnormal glucose tolerance, decreased serum high-density-lipoprotein cholesterol, increased serum low-density-lipoprotein cholesterol, and elevation of liver-function test values and rarely cholestatic jaundice. Some patients may experience palpitations, tachycardia, and hypertension. Benign intracranial hypertension and visual disturbances have occurred.

Effects on carbohydrate metabolism. Diabetes mellitus developed in a patient given danazol 400 mg twice daily for endometriosis.¹ The diabetes developed 8 weeks after starting danazol therapy and resolved completely after the drug was stopped.

- Seifer DB, et al. Insulin-dependent diabetes mellitus associated with danazol. *Am J Obstet Gynecol* 1990; **162**: 474–5.

Effects on the liver. As with other 17 α -alkylated steroids (see p.2130), hepatic adverse effects have been associated with danazol, including hepatitis¹ and cholestasis.^{2,3} Hepatic adenoma has occurred after long-term danazol use.^{4,7} Adenomas are often removed surgically because of the risks of haemorrhage and malignant transformation, but regression over 18 months and 2 years after stopping danazol has been described in 2 patients.⁶ There have also been rare reports of focal nodular hyperplasia,^{7,8} hepatocellular carcinoma,⁹ and peliosis hepatis.¹⁰

A case of acute hepatic failure has been attributed to danazol in a patient already taking ciclosporin (see below).

- Ohsawa T, Iwashita S. Hepatitis associated with danazol. *Drug Intell Clin Pharm* 1986; **20**: 889.
- Boue F, et al. Danazol and cholestatic hepatitis. *Ann Intern Med* 1986; **105**: 139–40.
- Bray GP, et al. Resolution of danazol-induced cholestasis with S-adenosylmethionine. *Postgrad Med J* 1993; **69**: 237–9.
- Fernand JP, et al. Danazol-induced hepatocellular adenoma. *Am J Med* 1990; **88**: 529–30.
- Bork K, et al. Hepatocellular adenomas in patients taking danazol for hereditary angio-oedema. *Lancet* 1999; **353**: 1066–7.
- Bork K, Schneiders V. Danazol-induced hepatocellular adenoma in patients with hereditary angio-oedema. *J Hepatol* 2002; **36**: 707–9.
- Bartley J, et al. Hepatocellular adenoma and focal nodular hyperplasia after long-term use of danazol for endometriosis: a case report. *Arch Gynecol Obstet* 2004; **269**: 290–3.
- Helsing P, Nielsen EW. Hepatocellular focal nodular hyperplasia after danazol treatment for hereditary angio-oedema. *Acta Derm Venereol* 2006; **86**: 272–3.

- Confavreux C, et al. Danazol-induced hepatocellular carcinoma. *QJM* 2003; **96**: 317–18.

- Makdisi WJ, et al. Fatal peliosis of the liver and spleen in a patient with agnogenic myeloid metaplasia treated with danazol. *Am J Gastroenterol* 1995; **90**: 317–8.

Effects on the pancreas. There have been reports of pancreatitis in patients receiving danazol.^{1,2}

- Chevalier X, et al. Danazol induced pancreatitis and hepatitis. *Clin Rheumatol* 1990; **9**: 239–41.
- Balasch J, et al. Acute pancreatitis associated with danazol treatment for endometriosis. *Hum Reprod* 1994; **9**: 1163–5.

Effects on the skin and hair. There have been isolated reports of erythema multiforme occurring in patients given danazol. In 3 cases the reaction developed about 2 weeks after starting danazol, and was effectively managed by stopping danazol and treating with corticosteroids.^{1,2}

Hirsutism is a recognised adverse effect of danazol, but is usually mild. Excessive facial hair growth of sudden onset, sufficient to cause distress, has been described in a woman given danazol for mastalgia. The hirsutism improved after stopping the danazol.³

- Gately LE, Andes WA. Danazol and erythema multiforme. *Ann Intern Med* 1988; **109**: 85.
- Reynolds NJ, Sansom JE. Erythema multiforme during danazol therapy. *Clin Exp Dermatol* 1992; **17**: 140.
- Zawar V, Sankalecha C. Facial hirsutism following danazol therapy. *Cutis* 2004; **74**: 301–3.

Precautions

Danazol should be used with caution in conditions that may be adversely affected by fluid retention, such as in cardiovascular, hepatic, and renal disorders; it should be avoided in marked dysfunction. It should also be used with care in patients with diabetes mellitus, polycythaemia, abnormal blood lipids, migraine, or epilepsy. Danazol should not be given to patients with undiagnosed genital bleeding or androgen-dependent tumours. As with other 17 α -alkylated compounds, there is an increased risk of liver disorders and liver function should be monitored during therapy. It should not be used in patients with a thromboembolic disorder or a history of thrombosis.

Danazol should not be given during pregnancy because of a possible androgenic effect on the female fetus (see below), and non-hormonal contraception is recommended during treatment. Caution is required in children and adolescents since precocious sexual development may occur in boys and virilisation in girls, and premature epiphyseal closure may occur in both sexes.

In the event of androgenic effects, danazol should be withdrawn, as they may prove irreversible on continued use.

Breast feeding. Licensed product information warns that danazol should be avoided in breast-feeding women because of the theoretical potential for androgenic effects in the infant.

Porphyria. Danazol has been associated with acute attacks of porphyria and is considered unsafe in porphyric patients.

Pregnancy. Reports of masculinisation of female infants born to mothers who had received danazol during pregnancy.^{1–3}

- Shaw RW, Farquhar JW. Female pseudohermaphroditism associated with danazol exposure in utero: case report. *Br J Obstet Gynaecol* 1984; **91**: 386–9.
- Kingsbury AC. Danazol and fetal masculinization: a warning. *Med J Aust* 1985; **143**: 410–11.
- Brunskill PJ. The effects of fetal exposure to danazol. *Br J Obstet Gynaecol* 1992; **99**: 212–15.

Interactions

Therapy with danazol may inhibit the hepatic metabolism of a number of drugs including carbamazepine (see p.475), ciclosporin (see below), and possibly tacrolimus (see p.1845). Danazol may also enhance the effects of warfarin (see Sex Hormones under Warfarin, p.1431). Introduction of danazol appeared to reduce the maintenance requirement for alfacalcidol (see p.1988). Rhabdomyolysis has been attributed to use of danazol with statins (see p.1393).

Ciclosporin. Danazol may raise ciclosporin concentrations (see p.1828), possibly by inhibiting its metabolism.

A case of fatal acute hepatic failure due to centrilobular massive hepatic necrosis was attributed to danazol in a patient already taking ciclosporin.¹ Danazol may have raised the ciclosporin concentrations in this case, but the authors speculated that an alternative interaction between the two drugs might have played a role in this reaction to danazol.

- Hayashi T, et al. Fatal acute hepatic failure induced by danazol in a patient with endometriosis and aplastic anemia. *J Gastroenterol* 2001; **36**: 783–6.

Pharmacokinetics

Danazol is absorbed from the gastrointestinal tract and metabolised in the liver; absorption is markedly increased if it is taken with food. A plasma elimination half-life of 3 to 6 hours has been reported after a single dose, but is increased to about 26 hours with repeated dosing. Ethisterone, 2-hydroxymethylethisterone, and 17-hydroxymethylethisterone are the major metabolites, though none have pituitary inhibiting activity. Danazol and its metabolites may undergo enterohepatic circulation. Metabolites are excreted in the urine and faeces.

Uses and Administration

Danazol suppresses the pituitary-ovarian axis by inhibiting pituitary output of gonadotrophins. It has weak androgenic activity.

Danazol has been given orally in the treatment of a variety of conditions including endometriosis, some benign breast disorders such as mastalgia and fibrocystic breast disease, gynaecomastia, menorrhagia associated with dysfunctional uterine bleeding, and prevention of hereditary angioedema. It may also be used for the pre-operative thinning of the endometrium prior to hysteroscopic endometrial ablation, and has been tried in other conditions including various blood disorders.

When given to women, treatment with danazol should be started on day 1 of the menstrual cycle or after pregnancy has been otherwise excluded.

In **endometriosis** the usual dose is 200 to 800 mg daily in 2 to 4 divided doses, adjusted according to the response. Therapy is given for 3 to 6 months or continued for up to 9 months if necessary.

In the treatment of **benign breast disorders** the usual initial dose is 100 to 400 mg daily in 2 divided doses, adjusted according to response, and continued for 3 to 6 months. For **gynaecomastia** 200 mg daily has been given to male adolescents, increased after 2 months to 400 mg daily if no response occurs; adult men have been given 400 mg daily initially, in up to 4 divided doses. Daily doses of up to 800 mg have been used, and therapy is usually tried for 6 months.

In dysfunctional uterine bleeding manifesting as **menorrhagia** doses of 200 mg daily have been given and treatment is reviewed after 3 months.

In the management of **hereditary angioedema** initial doses of 200 mg two or three times daily are given, and then reduced according to the patient's response.

For **pre-operative thinning** of the endometrium danazol has been given in a dose of 400 to 800 mg daily in up to 4 divided doses, for 3 to 6 weeks.

Blood disorders. Although danazol may produce thrombocytopenia and leucopenia its use has also been investigated in some blood disorders. Increased platelet counts have been reported in patients with *idiopathic thrombocytopenic purpura* (p.1505). Small cohort studies have reported response rates of about 60 to 70%, including both partial and complete responses,¹⁻³ with a mean or median time to response of about 3 months.^{1,2} Analysis of data from 96 patients suggested that age, sex, and spleen status may affect the response to danazol.² The response in men was not affected by age, but was better in splenectomised patients. However, in women there was a better response rate with advancing age in unsplenectomised patients, and the benefit of splenectomy on rates of response to danazol was only seen in younger women (45 years or younger). A better overall response rate in older patients (60 years and older) was also reported in another group.⁴ However, others have found only a trend to less frequent response in younger patients, and no apparent relationship between response and sex or prior splenectomy.¹ *Thrombocytopenia associated with rheumatic disorders*, such as SLE, the antiphospholipid antibody syndrome, and rheumatoid arthritis has also been reported to respond to treatment with danazol.⁵⁻⁷ For mention of the use of danazol in *Henoch-Schönlein purpura* see Hypersensitivity Vasculitis, p.1505.

Additionally there have been reports of response to danazol therapy in patients with *auto-immune haemolytic anaemia*^{8,9} (p.1043), anaemia of *myelofibrosis with myeloid metaplasia*,¹⁰ *paroxysmal nocturnal haemoglobinuria*,¹¹ *hereditary haemorrhagic telangiectasia*,¹² and *Evan's syndrome* due to SLE.¹³

There have been conflicting reports in patients with *myelodysplastic syndromes*.¹⁴⁻¹⁸

1. Maloisi F, *et al.* Danazol therapy in patients with chronic idiopathic thrombocytopenic purpura: long-term results. *Am J Med* 2004; **116**: 590-4.
2. Ahn YS, *et al.* Long-term danazol therapy in autoimmune thrombocytopenia: unmaintained remission and age-dependent response in women. *Ann Intern Med* 1989; **111**: 723-9.
3. Zimmer J, *et al.* Current management of adult idiopathic thrombocytopenic purpura in practice: a cohort study of 201 patients from a single center. *Clin Lab Haematol* 2004; **26**: 137-42.
4. Andrés E, *et al.* Idiopathic thrombocytopenic purpura: a retrospective analysis in 139 patients of the influence of age on the response to corticosteroids, splenectomy and danazol. *Drugs Aging* 2003; **20**: 841-6.
5. Blanco R, *et al.* Successful therapy with danazol in refractory autoimmune thrombocytopenia associated with rheumatic diseases. *Br J Rheumatol* 1997; **36**: 1095-9.
6. Arnal C, *et al.* Treatment of severe immune thrombocytopenia associated with systemic lupus erythematosus: 59 cases. *J Rheumatol* 2002; **29**: 75-83.
7. Aviña-Zubieta JA, *et al.* Long-term effectiveness of danazol corticosteroids and cytotoxic drugs in the treatment of hematologic manifestations of systemic lupus erythematosus. *Lupus* 2003; **12**: 52-7.
8. Ahn YS, *et al.* Danazol therapy for autoimmune hemolytic anemia. *Ann Intern Med* 1985; **102**: 298-301.
9. Tan AM, *et al.* Danazol for treatment of refractory autoimmune hemolytic anaemia. *Ann Acad Med Singapore* 1989; **18**: 707-9.
10. Cervantes F, *et al.* Efficacy and tolerability of danazol as a treatment for the anaemia of myelofibrosis with myeloid metaplasia: long-term results in 30 patients. *Br J Haematol* 2005; **129**: 771-5.
11. Harrington WJ, *et al.* Danazol for paroxysmal nocturnal hemoglobinuria. *Am J Hematol* 1997; **54**: 149-54.
12. Haq AU, *et al.* Hereditary hemorrhagic telangiectasia and danazol. *Ann Intern Med* 1988; **109**: 171.
13. Aranegui P, *et al.* Danazol for Evan's syndrome due to SLE. *DICP Ann Pharmacother* 1990; **24**: 641-2.
14. Wattel E, *et al.* Androgen therapy in myelodysplastic syndromes with thrombocytopenia: a report on 20 cases. *Br J Haematol* 1994; **87**: 205-8.
15. Chabannon C, *et al.* A review of 76 patients with myelodysplastic syndromes treated with danazol. *Cancer* 1994; **73**: 3073-80.
16. Letendre L, *et al.* Myelodysplastic syndrome treatment with danazol and cis-retinoic acid. *Am J Hematol* 1995; **48**: 233-6.
17. Viniou N, *et al.* Danazol therapy for thrombocytopenia in patients with myelodysplastic syndromes. *Acta Haematol (Basel)* 2002; **107**: 234-6.
18. Chan G, *et al.* Danazol for the treatment of thrombocytopenia in patients with myelodysplastic syndrome. *Am J Hematol* 2002; **71**: 166-71.

Endometriosis. Endometriosis is a condition affecting women mainly in their reproductive years, and caused by endometrial tissue developing outside the uterine cavity. It occurs most often in the pelvic peritoneal cavity and occasionally elsewhere such as the thoracic cavity. The aetiology is uncertain, although it is widely believed that retrograde flow of menstrual tissue introduces endometrial cells into the pelvic cavity, and that the implantation and growth of these cells may be influenced by genetic, immunologic, hormonal, and environmental factors.^{1,2}

The presentation of endometriosis is variable, and while symptoms can range from mild to severe, many affected women are asymptomatic.³ There is considerable overlap of symptoms with other conditions such as irritable bowel syndrome and pelvic inflammatory disease, but a definitive diagnosis of endometriosis can be made by visualisation at laparoscopy. The most common symptom is pain, usually manifesting as secondary dysmenorrhoea, dyspareunia, or cyclical back or pelvic pain. Pain may occur on micturition or defaecation if endometriosis affects the bladder or bowel; fibrosis and adhesions can develop. Endometriosis is also strongly associated with infertility. Severe endometriosis can distort the pelvic anatomy and thereby reduce fecundity, but how minimal and mild disease might affect fertility is unclear.^{1,4} Management will depend in part on the presenting complaint, the extent of disease, and whether fertility is an issue. Conservative laparoscopic surgery or drug therapy may be used, but disease recurrence is common and long-term management is usually needed.^{1,5} Nevertheless, spontaneous regression may occur in about a third of patients.^{4,5}

Where **infertility** is the presenting symptom, surgery is generally performed in more severe disease, based on the assumption that correction of anatomical defects should improve fecundity although there is a lack of controlled studies to confirm this.^{2,3,6,7} There is also limited evidence to suggest that surgery may improve fertility in mild disease,³ but it is likely that the effect is small.⁷ Assisted reproductive techniques such as IVF (see Infertility, p.2080) offer the best chance of conception in more severe disease.^{6,7} The extent of benefit in mild or moderate endometriosis is less clear.⁶ Superovulation with intra-uterine insemination may be considered in such cases, with IVF an alternative for women aged 35 or more, and postoperative expectant management another option in younger women.⁷

Drug therapy has not been shown to be of direct value for infertility.^{7,8} Also, because the drugs used for endometriosis tend to suppress ovulation and are potentially contraceptive, they will delay the opportunity for conception during treatment.^{3,6,9} Pre- and postoperative drug therapy have also been tried, but there is insufficient evidence to show that these are any more effective than surgery alone.¹⁰

For patients whose primary symptom is **pain**, drug treatments that cause anovulatory hypoestrogenism (to induce atrophy and shrinkage of the hormonally sensitive ectopic endometrial deposits) are effective and are the mainstay of treatment.⁴

One of the most widely used treatments has been *danazol*, which produces subjective improvement in symptoms of pain and reduction of some pelvic abnormalities and tissue implants.^{1,11} Its androgenic effects can be a problem and there is concern about its effect on blood lipids, therefore therapy is restricted to 6 months, or rarely up to 9 months. *Gestrinone* has been shown to be equally effective and may be a useful alternative.^{3,8,12} *Progestogens* such as medroxyprogesterone acetate, dydrogesterone, or norethisterone acetate are also commonly used. They appear to be as effective as danazol in relieving pain symptoms¹² and tend to be better tolerated.^{1,4} The use of local levonorgestrel from an intra-uterine device is also under investigation.²

Combined oral contraceptives are often used to relieve endometriosis pain, although the evidence for their benefit is largely observational¹ and data from controlled studies remain scanty.¹³ They have been used in a continuous fashion to induce amenorrhoea, as well as the usual cyclical regimens, but it is unclear which is most effective.^{3,8}

The other major group of drugs that are used in endometriosis are *gonadorelin* and its analogues such as buserelin, goserelin, leuprorelin, nafarelin, and triptorelin, which are as effective as danazol.^{1,6} Long-term use is limited by the risk of osteoporosis, but concomitant 'add-back' therapy such as low-dose oestrogen and progestogen HRT,^{1,3,6,8} or tibolone,^{1,3} can be used to prevent this. Adverse effects resembling menopausal symptoms can also be relieved by 'add-back' therapy, which may make gonadorelin analogues more tolerable than danazol.⁴ Parathyroid hormone^{14,15} may also be effective for 'add-back' therapy to prevent bone loss.

Investigational drugs include the *antiprogestogens* such as mifepristone,^{1,6} and *aromatase inhibitors* such as anastrozole.¹⁷

There is some evidence that laparoscopic ablation can also reduce pain but controlled studies are limited.^{4,6} Ideally, endometrial deposits found during diagnostic laparoscopy should be removed during the procedure.^{3,8,18} There is a lack of comparison between surgery and drug treatment. Although there are reports of improved pain control using postoperative medical therapy,¹⁸ study results have been mixed and there is insufficient evidence to confirm whether a combination of surgery and drug therapy has any additional benefit.^{6,10}

There is a relatively high recurrence rate of endometriosis after conservative surgery and drug therapy. In women who can accept loss of child-bearing potential, definitive therapy is surgical oophorectomy and hysterectomy with complete excision or ablation of endometrial deposits.^{3,8,18} Oestrogen replacement therapy is given, but carries a risk of recurrence of the disease; some have suggested that combined HRT may be preferable (see p.2075).

1. Crosignani P, *et al.* Advances in the management of endometriosis: an update for clinicians. *Hum Reprod Update* 2006; **12**: 179-89.
2. Hompes PGA, Mijatovic V. Endometriosis: the way forward. *Gynecol Endocrinol* 2007; **23**: 5-12.
3. Royal College of Obstetricians and Gynaecologists. The investigation and management of endometriosis (green-top guideline no. 24, issued October 2006). Available at: http://www.rcog.org.uk/resources/Public/pdf/endometriosis_gt_24_2006.pdf (accessed 30/06/08)
4. Child TJ, Tan SL. Endometriosis: aetiology, pathogenesis and treatment. *Drugs* 2001; **61**: 1735-50.
5. Farquhar C. Endometriosis. *BMJ* 2007; **334**: 249-53.
6. Olive DL, Pritts EA. The treatment of endometriosis: a review of the evidence. *Ann NY Acad Sci* 2002; **955**: 360-72.
7. Practice Committee of the American Society for Reproductive Medicine. Endometriosis and infertility. *Fertil Steril* 2006; **86** (suppl 4): S156-S160.
8. European Society for Human Reproduction and Embryology. ESHRE guideline for the diagnosis and treatment of endometriosis (last updated 30th June, 2007). Available at: <http://guidelines.endometriosis.org/index.html> (accessed 30/06/08)
9. Hughes E, *et al.* Ovulation suppression for endometriosis. Available in The Cochrane Database of Systematic Reviews; Issue 3. Chichester: John Wiley; 2007 (accessed 30/06/08).
10. Yap C, *et al.* Pre and post operative medical therapy for endometriosis surgery. Available in The Cochrane Database of Systematic Reviews; Issue 3. Chichester: John Wiley; 2004 (accessed 30/06/08).
11. Selak V, *et al.* Danazol for pelvic pain associated with endometriosis. Available in The Cochrane Database of Systematic Reviews; Issue 4. Chichester: John Wiley; 2007 (accessed 30/06/08).
12. Prentice A, *et al.* Progestagens and anti-progestagens for pain associated with endometriosis. Available in The Cochrane Database of Systematic Reviews; Issue 2. Chichester: John Wiley; 2000 (accessed 30/06/08).
13. Davis L, *et al.* Modern combined oral contraceptives for pain associated with endometriosis. Available in The Cochrane Database of Systematic Reviews; Issue 3. Chichester: John Wiley; 2007 (accessed 30/06/08).
14. Finkelstein JS, *et al.* Parathyroid hormone for the prevention of bone loss induced by estrogen deficiency. *N Engl J Med* 1994; **331**: 1618-23.
15. Finkelstein JS, *et al.* Prevention of estrogen deficiency-related bone loss with human parathyroid hormone (1-34): a randomized controlled trial. *JAMA* 1998; **280**: 1067-73.
16. Kettel LM, *et al.* Preliminary report on the treatment of endometriosis with low-dose mifepristone (RU 486). *Am J Obstet Gynecol* 1998; **178**: 1151-6.
17. Amsterdam LL, *et al.* Anastrozole [sic] and oral contraceptives: a novel treatment for endometriosis. *Fertil Steril* 2005; **84**: 300-304.
18. Practice Committee of the American Society for Reproductive Medicine. Treatment of pelvic pain associated with endometriosis. *Fertil Steril* 2006; **86** (suppl 4): S18-S27.

Gynaecomastia. Gynaecomastia is a common benign glandular enlargement of the male breast, caused either by increased oestrogenic activity or decreased androgenic activity. Examples of gynaecomastia caused by increased oestrogenic activity include oestrogen-secreting malignancies, increased aromatisation of androgens into oestrogens (associated with an increase in adipose tissue), and exposure to drugs with oestrogenic activity such as digitoxin. Neonatal and pubertal gynaecomastia also come into this category, the former due to exposure to maternal oestrogens and the latter because oestrogen levels increase before androgens do. Gynaecomastia caused by decreased androgenic activity may be associated with the natural decline of testosterone concentrations in ageing men, various forms of hypogonadism, increased metabolism of androgens (for example in alcoholism), and exposure to drugs with anti-androgenic properties such as spironolactone, cimetidine, ketoconazole, cyproterone acetate, or flutamide. Some systemic disorders may also be associated with gynaecomastia, including cirrhosis of the liver, hyperthyroidism, and renal failure; it may also occur on refeeding after starvation.

Gynaecomastia has a high rate of spontaneous regression, and specific therapy (other than the removal of any cause) need only be considered if the enlarged breast tissue causes sufficient pain, embarrassment, or emotional discomfort to interfere with the patient's daily life.^{1,3} Drug therapy is only likely to be of benefit while tissue is still proliferating; once glandular tissue has become inactive and fibrotic (usually after more than 12 months) a complete response is unlikely.^{2,3}

Except in primary hypogonadism,³ testosterone itself is unlikely to be of benefit (and may be aromatised to oestradiol, exacerbating the situation),² but a non-aromatisable androgen such as *androstano*lone (dihydrotestosterone) may produce some benefit.^{2,4} Danazol has produced marked responses in some patients,⁴ but adverse effects may limit its usefulness.² Quite good responses have also been reported with *tamoxifen*,^{4,6} and this has been recommended as a drug of choice.^{2,3} A retrospective review⁷ of men treated for idiopathic gynaecomastia found that a complete response occurred in 18 of 23 men treated with tamoxifen, but in only 8 of 20 who received danazol. The decrease in pain was similar for both groups, but relapse occurred in 5 of the men treated with tamoxifen. The use of other drugs with anti-oestrogen effects, such as *clomifene*^{8,9} and *raloxifene*,⁶ has also been described in small numbers of boys with pubertal gynaecomastia. Aromatase inhibitors have been investigated for their potential to prevent the peripheral aromatisation of androgens to oestrogens. Improvement in pubertal gynaecomastia has been reported with *testolactone*,¹⁰ but a controlled study¹¹ in 80 boys found 6 months of treatment with *anastrozole* to be no better than placebo. Studies in men being treated for prostate cancer also found *anastrozole* to be ineffective for the prevention^{12,13} and treatment¹² of gynaecomastia associated with bicalutamide therapy; in comparison, tamoxifen was effective in both studies.

Where drug therapy is unsuccessful, or the breast enlargement is long-standing, surgical removal of breast tissue is advocated.^{2,3} Prophylactic low-dose radiotherapy to the breast can significantly reduce the risk of gynaecomastia and breast pain in men undergoing anti-androgen treatment for prostate cancer,² although comparative studies suggest that it may be less effective than tamoxifen.^{14,15}

- Bembo SA, Carlson HE. Gynecomastia: its features, and when and how to treat it. *Cleve Clin J Med* 2004; **71**: 511–17.
- Gikas P, Mokbel K. Management of gynecomastia: an update. *Int J Clin Pract* 2007; **61**: 1209–15.
- Braunstein GD. Gynecomastia. *N Engl J Med* 2007; **357**: 1229–37.
- Gruntmanis U, Braunstein GD. Treatment of gynecomastia. *Curr Opin Investig Drugs* 2001; **2**: 643–9.
- McDermott MT, et al. Tamoxifen therapy for painful idiopathic gynecomastia. *South Med J* 1990; **83**: 1283–5.
- Lawrence SE, et al. Beneficial effects of raloxifene and tamoxifen in the treatment of pubertal gynecomastia. *J Pediatr* 2004; **145**: 71–6.
- Ting ACW, et al. Comparison of tamoxifen with danazol in the management of idiopathic gynecomastia. *Am Surg* 2000; **66**: 38–40.
- LeRoith D, et al. The effect of clomiphene citrate on pubertal gynecomastia. *Acta Endocrinol (Copenh)* 1980; **95**: 177–80.
- Plourde PV, et al. Clomiphene in the treatment of adolescent gynecomastia: clinical and endocrine studies. *Am J Dis Child* 1983; **137**: 1080–2.
- Zachmann M, et al. Treatment of pubertal gynecomastia with testolactone. *Acta Endocrinol (Copenh)* 1986; **279** (suppl): 218–26.
- Plourde PV, et al. Safety and efficacy of anastrozole for the treatment of pubertal gynecomastia: a randomized, double-blind, placebo-controlled trial. *J Clin Endocrinol Metab* 2004; **89**: 4428–33.
- Saltzstein D, et al. Prevention and management of bicalutamide-induced gynecomastia and breast pain: randomized endocrinologic and clinical studies with tamoxifen and anastrozole. *Prostate Cancer Prostatic Dis* 2005; **8**: 75–83.
- Boccardo F, et al. Evaluation of tamoxifen and anastrozole in the prevention of gynecomastia and breast pain induced by bicalutamide monotherapy of prostate cancer. *J Clin Oncol* 2005; **23**: 808–15.
- Perdonà S, et al. Efficacy of tamoxifen and radiotherapy for prevention and treatment of gynecomastia and breast pain caused by bicalutamide in prostate cancer: a randomised controlled trial. *Lancet Oncol* 2005; **6**: 295–300.
- Di Lorenzo G, et al. Gynecomastia and breast pain induced by adjuvant therapy with bicalutamide after radical prostatectomy in patients with prostate cancer: the role of tamoxifen and radiotherapy. *J Urol (Baltimore)* 2005; **174**: 2197–2203.

Hereditary angioedema. Danazol has been used successfully^{1,2} to prevent attacks of hereditary angioedema (p.1081). Patients with lupus erythematosus-like syndromes associated with hereditary angioedema have also benefited from danazol therapy.^{3,5}

- Bowen T, et al. Canadian 2003 international consensus algorithm for the diagnosis, therapy, and management of hereditary angioedema. *J Allergy Clin Immunol* 2004; **114**: 629–37.
- Gompels MM, et al. C1 inhibitor deficiency: consensus document. *Clin Exp Immunol* 2005; **139**: 379–94. Correction. *ibid.*; **141**: 189–90. [dose]
- Masse R, et al. Reversal of lupus-erythematosus-like disease with danazol. *Lancet* 1980; **ii**: 651.
- Donaldson VH, Hess EV. Effect of danazol on lupus-erythematosus-like disease in hereditary angioneurotic oedema. *Lancet* 1980; **ii**: 1145.
- Duhra P, et al. Discoid lupus erythematosus associated with hereditary angioneurotic oedema. *Br J Dermatol* 1990; **123**: 241–4.

Mastalgia. Mastalgia may occur alone or be associated with nodularity or other fibrocystic changes in the female breast. It is usually divided into cyclical mastalgia, which accounts for about two-thirds of all cases, non-cyclical mastalgia, and chest-wall or costochondral pain (Tietze's syndrome). Cyclical mastalgia has a temporal association with the menstrual cycle and is most common in the third decade of life, with a chronic relapsing course thereafter; it usually resolves at the menopause. Non-cyclical mastalgia tends to present later in life as constant or intermittent pain that is not associated with the menstrual cycle.

Once clear pathological causes of pain have been excluded most patients can be managed by simple reassurance.^{1,3} In the management of mild mastalgia, simple measures such as wearing a properly fitting brassiere and the use of relaxation techniques are widely recommended.^{1,3} Warm compresses or ice packs and gentle massage may provide relief, particularly when the pain is cyclic or intermittent and of short duration.¹ There is some evidence that a low-fat diet may reduce symptoms of mastalgia, but the evidence to support a restriction of dietary caffeine intake is inconsistent and such a measure is not generally recommended.^{1,3} Although few studies have been done to confirm a beneficial effect, many women are likely to self-medicate as required with simple analgesics such as paracetamol or oral or topical NSAIDs.¹ Patients who take an oral contraceptive or HRT may find that symptoms improve on reducing the estrogen dose or stopping treatment.^{1,3}

Women with moderate to severe mastalgia that has lasted for more than 6 months may require specific drug treatment. *Danazol* is probably the most effective drug for mastalgia, and studies suggest that it is of benefit in about 70% or more of patients with cyclical mastalgia,^{1,3} and somewhat fewer with the non-cyclical form.² However, adverse effects may force the dose to be reduced or stopped. Danazol given only during the luteal phase (days 14 to 28) has been reported to be effective in cyclical mastalgia, and to cause few adverse effects.⁴ *Gestronone* has also been reported to be effective in cyclical mastalgia.¹ Although effective in cyclical mastalgia,^{3,5} *bromocriptine* is not as effective as danazol, and its use is similarly limited by adverse effects.^{1,2} A small study⁶ has reported that *lisuride* was effective in cyclical mastalgia.

Gamolenic acid (usually as evening primrose oil) has been widely used in cyclical mastalgia because of early studies suggesting that it was an effective treatment with few adverse effects. Although further studies have produced conflicting results and there is now doubt about its efficacy,^{2,3,5} some still suggest that it can be tried as there may be a beneficial effect with minimal risk.¹

In refractory cyclical or non-cyclical mastalgia *tamoxifen*^{3,5} has been shown to be effective; controlled trials have reported efficacy rates of up to 96% in cyclical mastalgia and 56% in non-cyclical mastalgia.¹ However, the concept of using tamoxifen in otherwise healthy premenopausal women has produced some concern.^{7–9} *Toremifene* has been reported to be of benefit.^{10,11} *Goserelin* has also been shown to be effective,^{12,13} but there is limited experience with the use of gonadorelin analogues and severe adverse effects are likely to limit their use.¹ Injection of a local anaesthetic with a corticosteroid has proved effective for the pain of non-cyclical mastalgia.¹⁴

Other drugs that have been used for cyclical mastalgia include antibacterials, diuretics, and various vitamins but there is no evidence that they are any better than placebo.¹

- Smith RL, et al. Evaluation and management of breast pain. *Mayo Clin Proc* 2004; **79**: 353–72.
- Gumm R, et al. Evidence for the management of mastalgia. *Curr Med Res Opin* 2004; **20**: 681–4.
- Rosolowich V, et al. Society of Obstetricians and Gynecologists of Canada. Mastalgia. *J Obstet Gynaecol Can* 2006; **28**: 49–57. Also available at: <http://www.sogc.org/guidelines/public/170E-CPG-January2006.pdf> (accessed 30/06/08)
- O'Brien PMS, Abukhalil IEH. Randomized controlled trial of the management of premenstrual syndrome and premenstrual mastalgia using luteal phase-only danazol. *Am J Obstet Gynecol* 1999; **180**: 18–23.
- Srivastava A, et al. Evidence-based management of mastalgia: a meta-analysis of randomised trials. *Breast* 2007; **16**: 503–12.
- Kaleli S, et al. Symptomatic treatment of premenstrual mastalgia in premenopausal women with lisuride maleate: a double-blind placebo-controlled randomized study. *Fertil Steril* 2001; **75**: 718–23.
- Anonymous. Tamoxifen for benign breast disease. *Lancet* 1986; **i**: 305.

- Smallwood JA, Taylor I. Tamoxifen for mastalgia. *Lancet* 1986; **i**: 680–1.
- Fentiman IS, et al. Tamoxifen for mastalgia. *Lancet* 1986; **i**: 681.
- Gong C, et al. A double-blind randomized controlled trial of toremifene therapy for mastalgia. *Arch Surg* 2006; **141**: 43–7.
- Oksa S, et al. Toremifene for premenstrual mastalgia: a randomised, placebo-controlled crossover study. *BJOG* 2006; **113**: 713–18.
- Hamed H, et al. LHRH analogue for treatment of recurrent and refractory mastalgia. *Ann R Coll Surg Engl* 1990; **72**: 221–4.
- Mansel RE, et al. European randomized, multicenter study of goserelin (Zoladex) in the management of mastalgia. *Am J Obstet Gynecol* 2004; **191**: 1942–9.
- Khan HN, et al. Local anaesthetic and steroid combined injection therapy in the management of non-cyclical mastalgia. *Breast* 2004; **13**: 129–32.

Menorrhagia. Danazol is effective in the treatment of menorrhagia (p.2126) but it is only used short term because of its adverse effects.¹ It may also be used for pre-operative endometrial thinning.²

- Beaumont H, et al. Danazol for heavy menstrual bleeding. Available in The Cochrane Database of Systematic Reviews; Issue 3. Chichester: John Wiley; 2007 (accessed 30/06/08).
- Sowter MC, et al. Pre-operative endometrial thinning agents before endometrial destruction for heavy menstrual bleeding. Available in The Cochrane Database of Systematic Reviews; Issue 3. Chichester: John Wiley; 2002 (accessed 30/06/08).

Premenstrual syndrome. Danazol may be useful^{1,3} in the management of the premenstrual syndrome (p.2099), but some have found it to be of value only for cyclical mastalgia rather than for general symptoms,⁴ and in any case adverse effects limit its long-term use.

- Halbreich U, et al. Elimination of ovulation and menstrual cyclicity (with danazol) improves dysphoric premenstrual syndromes. *Fertil Steril* 1991; **56**: 1066–9.
- Deeny M, et al. Low dose danazol in the treatment of the premenstrual syndrome. *Postgrad Med J* 1991; **67**: 450–4.
- Hahn PM, et al. A randomized, placebo-controlled, crossover trial of danazol for the treatment of premenstrual syndrome. *Psychoneuroendocrinology* 1995; **20**: 193–209.
- O'Brien PMS, Abukhalil IEH. Randomized controlled trial of the management of premenstrual syndrome and premenstrual mastalgia using luteal phase-only danazol. *Am J Obstet Gynecol* 1999; **180**: 18–23.

Skin disorders. Danazol has been reported to relieve pruritus (p.1582) refractory to usual treatment with antihistamines; underlying conditions have included cholinergic urticaria,^{1,2} chronic actinic dermatitis,³ myeloproliferative disorders,⁴ and autoimmune disorders.⁴ In 2 reports, the skin disorder had been associated with low plasma concentrations of antiprotease.^{1,3} Danazol has generally been given in oral doses of 200 to 800 mg daily.⁴ Maintenance treatment may be needed, and relapse can occur when the dose is reduced or treatment is withdrawn.

Danazol was also reported to reduce induration and pain in a man with lipodermatosclerosis.⁵

- Berth-Jones J, Graham-Brown RAC. Cholinergic pruritus, erythema and urticaria: a disease spectrum responding to danazol. *Br J Dermatol* 1989; **121**: 235–7.
- La Shell MS, England RW. Severe refractory cholinergic urticaria treated with danazol. *J Drugs Dermatol* 2006; **5**: 664–7.
- Humbert P, et al. Chronic actinic dermatitis responding to danazol. *Br J Dermatol* 1991; **124**: 195–7.
- Kolodny L, et al. Danazol relieves refractory pruritus associated with myeloproliferative disorders and other diseases. *Am J Hematol* 1996; **51**: 112–16.
- Hafner C, et al. Lipodermatosclerosis: successful treatment with danazol. *Acta Derm Venereol* 2005; **85**: 365–6.

Preparations

USP 31: Danazol Capsules.

Proprietary Preparations (details are given in Part 3)

Arg.: Ladogal; **Austral.:** Azol; **Danocrine;** **Austria:** Danokrin; **Belg.:** Danatrol; **Braz.:** Ladogal; **Canada:** Cyclomen; **Chile:** Danogarl; **Cz.:** Anargil; **Danolt;** Danoval; **Dennm.:** Danocrine; **Fin.:** Danocrine; **Fr.:** Danatrol; **Gr.:** Danatrol; **Hong Kong:** Anargil; **Danocrine;** **Hung.:** Danoval; **India:** Danogen; **Gonabok;** Zendol; **Indon.:** Azol; **Danocrine;** **Ir.:** Ladazant; **Danolt;** **Israel:** Danol; **Ital.:** Danatrol; **Jpn:** Bonzoli; **Malaysia:** Anargil; **Azol;** Ladogal; **Vabon;** **Mex.:** Danalem; **Kendazol;** Ladogal; **Novaprin;** Zoldan-A; **Neth.:** Danatrol; **Norw.:** Danocrine; **NZ:** D-Zol; **Danocrine;** **Philipp.:** Ladogal; **Port.:** Danatrol; **Mastodanotrol;** **Rus.:** Danoval (Дановал); **S.Afr.:** Danogen; **Ladazol;** **Singapore:** Azol; **Ladogal;** **Spain:** Danatrol; **Swed.:** Danocrine; **Switz.:** Danatrol; **Thai.:** Anargil; **Ectopal;** Ladogal; **Vabon;** **Turk.:** Danasin; **UK:** Danol; **USA:** Danocrine; **Venez.:** Danogen; **Ladogal.**

Degarelix (USAN, rINN)

Dégarelix; Degarelixum; FE-200486 (degarelix acetate). N-Acetyl-3-(naphthalen-2-yl)-D-alanyl-4-chloro-D-phenylalanyl-3-(pyridin-3-yl)-D-alanyl-L-seryl-4-(([(4S)-2,6-dioxohexahydropyrimidin-4-yl]carbonyl)amino)-L-phenylalanyl-4-(carbamoylamino)-D-phenylalanyl-L-leucyl-N⁶-(1-methylthyl)-L-lysyl-L-prolyl-D-alaninamide.

Дегареликс

C₈₂H₁₀₃ClN₁₈O₁₆ = 1632.3.

CAS = 214766-78-6.