

fusion over 2 hours. A longer infusion time should be considered in children weighing less than 20 kg to reduce anxiety and irritability, and to avoid high clofarabine concentrations. The course may be repeated every 2 to 6 weeks, depending on the patient's recovery from bone-marrow depression and other adverse effects. Treatment is usually assessed after 2 treatment cycles.

Clofarabine is under investigation for the treatment of acute myeloid leukaemia, myelodysplastic syndrome, and solid tumours.

References.

- Kantarjian HM, et al. Phase I clinical and pharmacology study of clofarabine in patients with solid and hematologic cancers. *J Clin Oncol* 2003; **21**: 1167-73.
- Gandhi V, et al. Pharmacokinetics and pharmacodynamics of plasma clofarabine and cellular clofarabine triphosphate in patients with acute leukemias. *Clin Cancer Res* 2003; **9**: 6335-42.
- Kantarjian H, et al. Phase 2 clinical and pharmacologic study of clofarabine in patients with refractory or relapsed acute leukemia. *Blood* 2003; **102**: 2379-86.
- Bonate PL, et al. Population pharmacokinetics of clofarabine, a second-generation nucleoside analog, in pediatric patients with acute leukemia. *J Clin Pharmacol* 2004; **44**: 1309-22.
- Jeha S, et al. Clofarabine, a novel nucleoside analog, is active in pediatric patients with advanced leukemia. *Blood* 2004; **103**: 784-9.
- Faderl S, et al. Results of a phase 1-2 study of clofarabine in combination with cytarabine (ara-C) in relapsed and refractory acute leukemias. *Blood* 2005; **105**: 940-7.
- Curran MP, Perry CM. Clofarabine: in pediatric patients with acute lymphoblastic leukemia. *Paediatr Drugs* 2005; **7**: 259-64.
- Kline JP, Larson RA. Clofarabine in the treatment of acute myeloid leukaemia and acute lymphoblastic leukaemia: a review. *Expert Opin Pharmacother* 2005; **6**: 2711-18.
- Kantarjian HM, et al. Clofarabine: past, present, and future. *Leuk Lymphoma* 2007; **48**: 1922-30.

Preparations

Proprietary Preparations (details are given in Part 3)

Cz.: Evoltra; **Fr.:** Evoltra; **Port.:** Evoltra; **UK:** Evoltra; **USA:** Clolar.

Combretastatin A4 Phosphate

CS-A4 (combretastatin A4); NSC-348103 (combretastatin). 2-Methoxy-5-[(1Z)-2-(3,4,5-trimethoxyphenyl)ethenyl]-phenol dihydrogen phosphate.

$C_{18}H_{21}O_8P = 396.3$.

CAS — 82855-09-2 (combretastatin); 117048-59-6 (combretastatin A4); 222030-63-9 (combretastatin A4 phosphate).

Profile

Combretastatin A4 phosphate is a synthetic derivative of combretastatin compounds originally isolated from the African bush-willow tree (Cape bush-willow; *Combretum cafrum*). It is described as a vascular targeting agent that reduces blood flow to tumours by disrupting the endothelial cells of newly formed blood vessels, and is under investigation for the treatment of thyroid and ovarian cancers.

Corynebacterium parvum

C. parvum; NSC-220537; *Propionibacterium acnes*.

Profile

Inactivated *Corynebacterium parvum* has been used in the treatment of malignancy effusions, and has been tried as an adjuvant to cancer chemotherapy for its immunostimulant properties. It has also been used in the treatment of musculoskeletal and joint disorders.

Fever and pain have occurred after intracavitary injection. There have been reports of nephrotoxicity after intravenous use.

Preparations

Proprietary Preparations (details are given in Part 3)

Ger.: Arthroheklan A.

Cyclophosphamide (BAN, rINN)

B-518; Ciclofosfamida; Ciklofosfamidas; Ciklofosfamid; Cyclophosphamidum; Cyclophosphamidum Monohydricum; Cyclophosphanum; Cyklofosfamid; Cyklofosfamid monohydrát; NSC-26271; Siklofosfamid; Syklofosfamid; VWR-138719. 2-[Bis(2-chloroethyl)amino]perhydro-1,3,2-oxazaphosphorinan 2-oxide monohydrate.

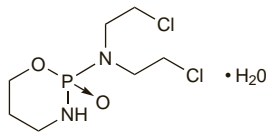
Циклофосфамид

$C_7H_{15}Cl_2N_2O_2P \cdot H_2O = 279.1$.

CAS — 6055-19-2 (cyclophosphamide monohydrate); 50-18-0 (anhydrous cyclophosphamide).

ATC — L01AA01.

ATC Vet — QL01AA01.



Pharmacopoeias. In *Chin.*, *Eur.* (see p.vii), *Int.*, *Jpn.*, and *US*.

Ph. Eur. 6.2 (Cyclophosphamide). A white or almost white, crystalline powder. Soluble in water; freely soluble in alcohol. A freshly prepared 2% solution in water has a pH of 4.0 to 6.0.

USP 31 (Cyclophosphamide). A white, crystalline powder. It liquefies upon loss of its water of crystallisation. Soluble in water and in alcohol. A 1% solution in water has a pH of 3.9 to 7.1 when determined 30 minutes after preparation. Store in airtight containers at 2° to 30°.

Adverse Effects and Treatment

For a general outline see Antineoplastics, p.635 and p.639. The major dose-limiting effect is myelosuppression. After single doses the nadir of the white cell count may occur in around 1 to 2 weeks with full recovery usually in 3 to 4 weeks. Thrombocytopenia and anaemia may occur but tend to be less common and less severe.

Haemorrhagic cystitis may develop after high or prolonged dosage, and can be life-threatening. Adequate hydration to maintain urine output at 100 mL/hour and use of mesna (see p.1449) are generally recommended in an attempt to reduce urotoxicity. If mesna is used, frequent emptying of the bladder should be avoided. Doses of cyclophosphamide should be given early in the day.

Alopecia occurs in about 20% of patients given low doses and in practically all patients given high doses. Hair loss starts after 3 weeks of treatment but regrowth is usually evident after 3 months, even with continued treatment. Hyperpigmentation of skin, especially that of the palms and soles, and of the nails, has been reported.

Nausea and vomiting commonly occur, and may be reduced by prophylactic antiemetics. Mucositis may also occur.

Other adverse effects include a syndrome resembling inappropriate secretion of antidiuretic hormone (which may require diuretic therapy), disturbances of carbohydrate metabolism, gonadal suppression (common and occasionally resulting in sterility), interstitial pulmonary fibrosis, and, especially at high doses, cardiotoxicity.

Cyclophosphamide, in common with other alkylating agents, has carcinogenic, mutagenic, and teratogenic potential and secondary malignancies have occurred in patients given previous antineoplastic therapy including cyclophosphamide—see p.635.

Effects on the bladder. *Sterile haemorrhagic cystitis* (p.2178) can occur after high-dose infusions of cyclophosphamide or after prolonged low-dose oral use.^{1,2} It is believed to be secondary to renal excretion of alkylating metabolites, particularly the acrolein metabolite, that cause sloughing, thinning, and inflammation of the bladder wall. Damage ranges from minor bleeding to diffuse necrotic ulceration, and can lead to anaemia, constriction of the bladder, bladder perforation, and death.² Symptoms may be delayed, and have been reported to occur up to 6 months after stopping the drug.³ An increased incidence of cystitis when patients on a high-dose cyclophosphamide regimen were transferred from one brand to another has been reported,⁴ apparently because one was labelled in terms of the anhydrous substance and one as the monohydrate, resulting in a 6.4% difference in the content of active substance.⁵

Measures used to prevent haemorrhagic cystitis include intravenous hydration with diuresis, frequent voiding, or bladder catheterisation with irrigation, to increase urine output and dilute the excreted metabolites. Mesna may be used as a uroprotectant to reduce exposure to the metabolites.² If bleeding occurs, various drugs have been instilled intravesically, including sodium chloride 0.9%, alum, or prostaglandins.^{2,6-9} Silver nitrate, formaldehyde, or phenol instillations have been used but are painful and patients require anaesthesia.² There is limited information to suggest that conjugated oestrogens given orally or intravenously may be effective.^{2,10} Nonpharmacological techniques are reserved for refractory cases and include arterial embolisation or surgery.²

In addition to the shorter term effects, cyclophosphamide has been reported to be associated with the development of *bladder carcinoma*.^{1,11-14} A history of cyclophosphamide-induced cystitis may be associated with an increased risk of bladder carcinoma^{1,11} but some studies have not found a link,¹³ and bladder malignancies can develop in patients who have not experienced cystitis while receiving cyclophosphamide.¹² For a discussion of the carcinogenic effects of antineoplastics, including cyclophosphamide, see p.635.

- Talar-Williams C, et al. Cyclophosphamide-induced cystitis and bladder cancer in patients with Wegener granulomatosis. *Ann Intern Med* 1996; **124**: 477-84.
- West NJ. Prevention and treatment of hemorrhagic cystitis. *Pharmacotherapy* 1997; **17**: 696-706.
- Armstrong B, et al. Delayed cystitis due to cyclophosphamide. *N Engl J Med* 1979; **300**: 45.
- Shaw IC, et al. Difference in bioactivity between two preparations of cyclophosphamide. *Lancet* 1983; **i**: 709.
- Hilgard P, et al. Bioactivity of cyclophosphamide preparations. *Lancet* 1983; **i**: 1436.
- Mohiuddin J, et al. Treatment of cyclophosphamide-induced cystitis with prostaglandin E. *Ann Intern Med* 1984; **101**: 142.
- Miller LJ, et al. Treatment of cyclophosphamide-induced hemorrhagic cystitis with prostaglandins. *Ann Pharmacother* 1994; **28**: 590-4.
- Ippoliti C, et al. Intravesicular carboprost for the treatment of hemorrhagic cystitis after marrow transplantation. *Urology* 1995; **46**: 811-15.
- Laszlo D, et al. Prostaglandin E2 bladder instillation for the treatment of hemorrhagic cystitis after allogeneic bone marrow transplantation. *Haematologica* 1995; **80**: 421-5.
- Ordemann R, et al. Encouraging results in the treatment of haemorrhagic cystitis with estrogen—report of 10 cases and review of the literature. *Bone Marrow Transplant* 2000; **25**: 981-5.
- Wall RL, Clausen KP. Carcinoma of the urinary bladder in patients receiving cyclophosphamide. *N Engl J Med* 1975; **293**: 271-3.
- Plotz PH, et al. Bladder complications in patients receiving cyclophosphamide for systemic lupus erythematosus or rheumatoid arthritis. *Ann Intern Med* 1979; **91**: 221-3.
- Pedersen-Bjergaard J, et al. Carcinoma of the urinary bladder after treatment with cyclophosphamide for non-Hodgkin's lymphoma. *N Engl J Med* 1988; **318**: 1028-32.
- Travis LB, et al. Bladder cancer after chemotherapy for non-Hodgkin's lymphoma. *N Engl J Med* 1989; **321**: 544-5.

Effects on the blood. Amifostine has been reported to protect against the myelosuppressive effects of cyclophosphamide, and may be used to reduce neutropenia-related infection associated with the combination of cyclophosphamide and cisplatin (see p.1437).

Effects on carbohydrate metabolism. Acute onset type 1 diabetes occurred in a patient treated with cyclophosphamide, doxorubicin, vincristine and prednisone (CHOP), and was thought to be due to the cyclophosphamide.¹

- Atlan-Geper C, et al. A cyclophosphamide-induced autoimmune diabetes. *Lancet* 1998; **352**: 373-4.

Effects on electrolytes. Water intoxication has been reported with cyclophosphamide,¹⁻⁴ usually in high doses (30 to 50 mg/kg or more) although symptoms have been reported after a dose of 20 mg/kg in a patient with renal disease,³ and in another patient with SLE but apparently normal renal function who received 10 mg/kg.⁴ One case of severe hyponatraemia leading to convulsions and death has been reported.⁵ Symptoms resemble the syndrome of inappropriate antidiuretic hormone secretion (SIADH)³ but plasma concentrations of antidiuretic hormone do not appear to be raised in these patients.³

- DeFronzo RA, et al. Water intoxication in man after cyclophosphamide therapy: time course and relation to drug activation. *Ann Intern Med* 1973; **78**: 861-9.
- Green TP, Mirkin BL. Prevention of cyclophosphamide-induced antidiuresis by furosemide infusion. *Clin Pharmacol Ther* 1981; **29**: 634-42.
- Bressler RB, Huston DP. Water intoxication following moderate-dose intravenous cyclophosphamide. *Arch Intern Med* 1985; **145**: 548-9.
- McCarron MO, et al. Water intoxication after low dose cyclophosphamide. *BMJ* 1995; **311**: 292.
- Harlow PJ, et al. A fatal case of inappropriate ADH secretion induced by cyclophosphamide therapy. *Cancer* 1979; **44**: 896-8.

Effects on the eyes. Recurrent transient myopia, apparently due to increased hydration of the lens of the eye, was induced by an intravenous bolus of cyclophosphamide in an adolescent with SLE.¹

CMV retinitis has occurred in patients during or after cyclophosphamide therapy; presenting symptoms included floaters and blurred or decreased vision.²

- Arranz JA, et al. Cyclophosphamide-induced myopia. *Ann Intern Med* 1992; **116**: 92-3.
- Agrawal A, et al. Visual symptoms in patients on cyclophosphamide may herald sight threatening disease. *Br J Ophthalmol* 2003; **87**: 122-3.

Effects on reproductive potential. Severe gonadal failure with transient or permanent azoospermia is common in men treated with cyclophosphamide. Suppression of germ-cell function with intramuscular testosterone in 5 men during cyclophosphamide therapy for nephrotic syndrome was associated with a more rapid return of spermatogenesis compared with 10 patients who did not receive the androgen.¹

- Masala A, et al. Use of testosterone to prevent cyclophosphamide-induced azoospermia. *Ann Intern Med* 1997; **126**: 292-5.

Effects on the skin. An erythematous pruritic rash, similar to the palmar-plantar erythrodysesthesia syndrome (p.639) but oc-