

but systemic chemotherapy is the treatment of choice.^{1,3,5,6} The main combination regimens use a vinca alkaloid and bleomycin, with or without doxorubicin.^{2,3} Liposomal formulations of doxorubicin and daunorubicin have produced response rates of 40–85%, and may be less toxic than conventional chemotherapy;^{2,3,8} it has been suggested that a liposomal anthracycline is the drug of choice in extensive disease.^{1,2,5–7} Paclitaxel is also used as a single agent in advanced disease.^{2,3,7,8} However, although highly effective, doses may need to be reduced if given to patients taking HAART because of the risk of drug interactions.^{5,7} Although data are limited, docetaxel may be a reasonable alternative.⁷ Some response has also been reported for oral etoposide.¹

Control of Kaposi's sarcoma has been reported in a few patients given high-dose intramuscular chorionic gonadotropin, but tumour regression ceased and regrowth occurred when dosage was reduced or withdrawn.⁹ Further reports of intralesional or systemic use have included partial remissions and disease stabilisation, as well as no effect or disease progression. The reasons for these contradictory results are unclear, but they may be due to variability in chorionic gonadotropin preparations, which contain a mixture of biological contaminants. A cytotoxic ribonuclease and the degradation product of the β -hCG subunit have been proposed as active contaminants against Kaposi's sarcoma, but other contaminants may stimulate the tumour.¹⁰ Other lines of investigation include the use of sulfated polysaccharide peptidoglycans, imatinib, other inhibitors of angiogenesis including thalidomide, and the retinoids.^{1,5–8}

1. Antman K, Chang Y. Kaposi's sarcoma. *N Engl J Med* 2000; **342**: 1027–38.
2. Mitsuyasu RT. Update on the pathogenesis and treatment of Kaposi sarcoma. *Curr Opin Oncol* 2000; **12**: 174–80.
3. Hermans P. Opportunistic AIDS-associated malignancies in HIV-infected patients. *Biomed Pharmacother* 2000; **54**: 32–40.
4. Stallone G, et al. Sirolimus for Kaposi's sarcoma in renal-transplant recipients. *N Engl J Med* 2005; **352**: 1317–23.
5. Cheung MC, et al. AIDS-related malignancies: emerging challenges in the era of highly active antiretroviral therapy. *Oncologist* 2005; **10**: 412–26.
6. Wilkins K, et al. Cutaneous malignancy and human immunodeficiency virus disease. *J Am Acad Dermatol* 2006; **54**: 189–206.
7. Di Lorenzo G, et al. Management of AIDS-related Kaposi's sarcoma. *Lancet Oncol* 2007; **8**: 167–76.
8. Dezube BJ, et al. Management of AIDS-related Kaposi sarcoma: advances in target discovery and treatment. *AIDS Read* 2004; **14**: 236–8, 243–4, 251–3.
9. Harris PJ. Treatment of Kaposi's sarcoma and other manifestations of AIDS with human chorionic gonadotropin. *Lancet* 1995; **346**: 118–19.
10. Simonart T, et al. Treatment of Kaposi's sarcoma with human chorionic gonadotropin. *Dermatology* 2002; **204**: 330–3.

SOFT-TISSUE SARCOMA. Soft-tissue sarcomas are a varied group of malignant tumours that originate from mesenchymal stem cells residing in muscle, fat, or connective tissue,^{1,2} and whose subtypes vary in terms of prognosis and response to different treatments.³ The majority of soft-tissue sarcomas occur in the limb or limb girdle; some occur within the abdomen (retroperitoneal), in the head or neck, or in the gastrointestinal tract.^{4,5} Patients have a 5-year survival rate of about 50 to 60%;⁴ survival in those with extremity sarcomas is better than that in patients with retroperitoneal sarcomas.² Tumours often metastasise to the lung; those arising in the abdomen metastasise to the liver and peritoneum.⁴

Rhabdomyosarcoma is the commonest soft-tissue sarcoma in childhood, and is thought to arise from progenitor cells for skeletal muscle. The most frequent sites are the head and neck, genito-urinary tract, and extremities. Some genetic disorders are associated with rhabdomyosarcoma.^{6,7} All patients are presumed to have micrometastatic disease at diagnosis; histologically the most common types are embryonal, which occurs at an earlier age, and alveolar, which is more common in adolescents.⁷

The **gastrointestinal stromal tumours (GISTs)** are soft-tissue sarcomas arising in the gastrointestinal tract, most commonly in the stomach and small bowel.^{4,8,9} Symptoms may include abdominal pain, anorexia, weight loss, haemorrhage, changes in bowel movements, bowel obstruction, or perforation. Patients with liver metastases may have oedema of the lower extremity, ascites, or jaundice.¹⁰ Spread to the lungs and other locations is seen only in advanced cases.⁴

Surgery is the primary therapy for soft-tissue sarcomas,^{1,2,4,8} and may be curative for localised disease.^{5,11} Radiotherapy, as external-beam therapy or brachytherapy, may be given with surgery, or alone if surgery is inappropriate or declined by the patient.⁵ Radiation may be given pre-operatively, during surgery, or postoperatively;¹ optimal

timing is unclear.^{5,8} Similar rates of local control and progression-free survival have been reported for pre- and postoperative radiotherapy, although pre-operative treatment has been associated with a greater incidence of wound complications, especially in lower extremity tumours.⁴ Postoperative radiation can cause acute and delayed bowel toxicity in those with retroperitoneal tumours, and significant toxicity has occurred with the use of brachytherapy, especially when used in the upper abdomen.² Surgery and/or radiotherapy may be combined with chemotherapy. Pre-operative chemotherapy may allow for more efficient resection of the tumour.^{1,8} The use of postoperative chemotherapy is controversial,^{5,8} except for some tumours such as extrasosseous Ewing's sarcoma or rhabdomyosarcoma. For these tumours, combinations of vincristine, dactinomycin, doxorubicin, cyclophosphamide, ifosfamide, or etoposide form the basis of most regimens.^{5,8}

For those with unresectable or metastatic disease, chemotherapy may be palliative; ifosfamide and doxorubicin are routinely used in this setting.⁵ These may be used as single agents or in combination; other acceptable single agent choices are dacarbazine, gemcitabine, or liposomal doxorubicin.⁴ Data support the use of adjuvant doxorubicin-based chemotherapy to improve disease-free survival;¹² however, overall survival is not improved. For palliative treatment in advanced soft-tissue sarcoma, a systematic review¹³ concluded that combination chemotherapy did not significantly increase survival rates compared with single-agent doxorubicin. A retrospective analysis¹⁴ found that, in patients with high-risk disease, clinical benefits of doxorubicin-based chemotherapy were not sustained beyond 1 year. There is no consensus on the best second-line chemotherapy regimen for patients with metastatic disease refractory to doxorubicin- or ifosfamide-based regimens.^{2,3} Dose-intensified combination regimens, with colony-stimulating factor support, have been investigated as adjuvant therapy¹⁵ and in advanced disease;¹⁶ although both these studies found a delay in disease progression, a beneficial effect on overall survival was only found in the former. Intensive combination chemotherapy benefited a subgroup of children with metastatic rhabdomyosarcoma and fewer than 2 unfavourable risk factors, in terms of event-free survival and overall survival. However, most patients have more than 2 risk factors; these patients should be considered for novel first-line therapies. No evidence was found for improved outcome after consolidation therapy with high-dose melphalan and autologous bone marrow or peripheral-blood stem cell rescue.¹⁷ Response to topotecan has been reported in a study of metastatic rhabdomyosarcoma,¹⁸ and trabectedin has shown some activity in advanced soft-tissue sarcomas.^{3,5} Tasonermin and melphalan can be used together for isolated limb perfusion of unresectable soft-tissue sarcomas, but severe toxicity may limit use of this regimen. Potential salvage therapy options after failure of first-line therapy include paclitaxel, docetaxel, gemcitabine, trofosfamide, temozolomide, and various combinations thereof.³

Surgery is used for localised, resectable disease arising in the gastrointestinal tract, although this does not routinely cure GISTs; median time to recurrence after resection is about 2 years. Adjuvant imatinib is under investigation in this setting. Imatinib produces durable clinical benefit and objective responses in most patients with GISTs, including those with metastatic or unresectable disease. If the tumour responds to imatinib, surgical resection may be indicated. In patients with imatinib-resistant GIST, or who experience life-threatening adverse effects such as hepatotoxicity and fluid retention with imatinib, sunitinib may be considered.^{4,8,9,19}

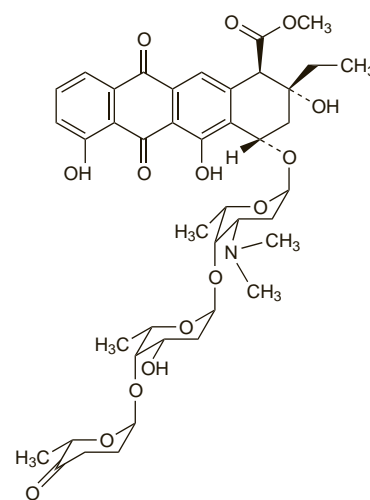
1. Mankin HJ, Hornicek FJ. Diagnosis, classification, and management of soft tissue sarcomas. *Cancer Control* 2005; **12**: 5–21.
2. Windham TC, Pisters PWT. Retroperitoneal sarcomas. *Cancer Control* 2005; **12**: 36–43.
3. Hartmann JT, Patel S. Recent developments in salvage chemotherapy for patients with metastatic soft tissue sarcoma. *Drugs* 2005; **65**: 167–78.
4. National Comprehensive Cancer Network. Clinical practice guidelines in oncology: soft tissue sarcoma (version 2.2008). Available at: http://www.nccn.org/professionals/physician_gls/PDF/sarcoma.pdf (accessed 17/06/08)
5. Clark MA, et al. Soft-tissue sarcomas in adults. *N Engl J Med* 2005; **353**: 701–11.
6. McDowell HP. Update on childhood rhabdomyosarcoma. *Arch Dis Child* 2003; **88**: 354–7.
7. Breitfeld PP, Meyer WH. Rhabdomyosarcoma: new windows of opportunity. *Oncologist* 2005; **10**: 518–27.
8. Skubitz KM, D'Adamo DR. Sarcoma. *Mayo Clin Proc* 2007; **82**: 1409–32.
9. Rubin BP, et al. Gastrointestinal stromal tumour. *Lancet* 2007; **369**: 1731–41. Correction. *ibid.*; **370**: 388.

10. D'Amato G, et al. Update on the biology and therapy of gastrointestinal stromal tumors. *Cancer Control* 2005; **12**: 44–56.
11. Pellitteri PK, et al. Management of sarcomas of the head and neck in adults. *Oral Oncol* 2003; **39**: 2–12.
12. Sarcoma Meta-analysis Collaboration (SMAC). Adjuvant chemotherapy for localised resectable soft tissue sarcoma in adults. Available in The Cochrane Database of Systematic Reviews; Issue 4. Chichester: John Wiley; 2000 (accessed 06/09/06).
13. Bramwell VHC, et al. Doxorubicin-based chemotherapy for the palliative treatment of adult patients with locally advanced or metastatic soft tissue sarcoma. Available in The Cochrane Database of Systematic Reviews; Issue 4. Chichester: John Wiley; 2001 (accessed 06/09/06).
14. Cormier JN, et al. Cohort analysis of patients with localized, high-risk, extremity soft tissue sarcoma treated at two cancer centers: chemotherapy-associated outcomes. *J Clin Oncol* 2004; **22**: 4567–74.
15. Frustaci S, et al. Adjuvant chemotherapy for adult soft tissue sarcomas of the extremities and girdles: results of the Italian randomized cooperative trial. *J Clin Oncol* 2001; **19**: 1238–47.
16. Le Cesne A, et al. Randomized phase III study comparing conventional-dose doxorubicin plus ifosfamide versus high-dose doxorubicin plus ifosfamide plus recombinant human granulocyte-macrophage colony-stimulating factor in advanced soft tissue sarcomas: a trial of the European Organization for Research and Treatment of Cancer/Soft Tissue and Bone Sarcoma Group. *J Clin Oncol* 2000; **18**: 2676–84.
17. Carli M, et al. European intergroup studies (MMT4-89 and MMT4-91) on childhood metastatic rhabdomyosarcoma: final results and analysis of prognostic factors. *J Clin Oncol* 2004; **22**: 4787–94. Correction. *ibid.* 2005; **23**: 248.
18. Pappo AS, et al. Up-front window trial of topotecan in previously untreated children and adolescents with metastatic rhabdomyosarcoma: an intergroup rhabdomyosarcoma study. *J Clin Oncol* 2001; **19**: 213–19.
19. Cowie F. Treatment of rare cancers: gastrointestinal stromal tumours. *Br J Hosp Med* 2006; **67**: 361–4.

Aclarubicin (BAN, USAN, rINN)

Adacinomycin A; Aclarubicina; Aclarubicine; Aclarubicinum; Aclarubisin; Aklarubisin; NSC-208734. Methyl (1R,2R,4S)-4-(O-[2,6-dideoxy-4-O-[(2R,6S)-tetrahydro-6-methyl-5-oxopyran-2-yl]- α -L-lyxo-hexopyranosyl])-(1 \rightarrow 4)-2,3,6-trideoxy-3-dimethylamino-L-lyxo-hexopyranosyloxy)-2-ethyl-1,2,3,4,6,11-hexahydro-2,5,7-trihydroxy-6,11-dioxonaphthacene-1-carboxylate.

Акларубинин
C₄₂H₅₃NO₁₅ = 811.9.
CAS — 57576-44-0.
ATC — L01DB04.
ATC Vet — QL01DB04.



Description. Aclarubicin is an anthracycline antineoplastic antibiotic isolated from *Streptomyces galilaeus*.

Aclarubicin Hydrochloride (BANM, rINN)

Aclarubicine, Chlorhydrate d'; Aclarubicini Hydrochloridum; Hidrocloruro de aclarubicina.

Акларубицина Гидрохлорид

C₄₂H₅₃NO₁₅·HCl = 848.3.

CAS — 75443-99-1.

ATC — L01DB04.

ATC Vet — QL01DB04.

Pharmacopoeies. In *Jpn*.

Stability. In a study of the stability of anthracycline antineoplastic agents in 4 infusion fluids—glucose 5%, sodium chloride 0.9%, lactated Ringer's injection, and a commercial infusion fluid—stability appeared to be partly related to pH; aclarubicin was